

# **Etiopathophysiological assessment of cases with chronic daily headache: A functional magnetic resonance imaging included investigation**

Received: 15 May 2012  
Accepted: 12 Aug 2012

Akram Hashemi<sup>1</sup>, Mohammad Torabi Nami<sup>2</sup>, Mohammad Ali Oghabian<sup>3</sup>, Habib Ganjgahi<sup>4</sup>, Zahra Vahabi<sup>1</sup>, Hajir Sikaroodi<sup>5</sup>

<sup>1</sup> Resident of neurology, Department of Neurology, Shariati Hospital, Tehran University of Medical Sciences, Tehran, Iran

<sup>2</sup> Resident of neuroscience, Department of Neuroscience, Institute for Cognitive Science Studies, Tehran AND Shiraz Neuroscience Research Center, Shiraz University of Medical Sciences, Shiraz, Iran

<sup>3</sup> Professor, Department of Medical Physics and Biomedical Engineering, Tehran University of Medical Sciences, Tehran, Iran

<sup>4</sup> MA, Department of Medical Physics and Biomedical Engineering, Tehran University of Medical Sciences, Tehran, Iran

<sup>5</sup> Assistant professor, Department of Neurology, Shariati Hospital, Tehran University of Medical Sciences, Tehran, Iran

## **Keywords**

Chronic Daily Headache, Functional MRI, Pathophysiology, Neuropsychology, Electroencephalography, TCD

## **Abstract**

**Background:** Chronic daily headache (CDH) has gained little attention in functional neuro-imaging. When no structural abnormality is found in CDH, defining functional correlates between activated brain regions during headache bouts may provide unique insights towards understanding the pathophysiology of this type of headache.

**Methods:** We recruited four CDH cases for comprehensive assessments, including history taking, physical examinations and neuropsychological evaluations (The Addenbrooke's Cognitive Evaluation, Beck's Anxiety and Depression Inventories, Pittsburg Sleep Quality Index and Epworth Sleepiness Scale). Visual analogue scale (VAS) was used to self-rate the intensity of headache. Patients then underwent electroencephalography (EEG), transcranial Doppler (TCD) and functional magnetic resonance imaging (fMRI) evaluations during maximal (VAS = 8-10/10) and off-headache (VAS = 0-3/10) conditions. Data were used to compare in both conditions. We also used BOLD (blood

oxygen level dependent) -group level activation map fMRI to possibly locate headache-related activated brain regions.

**Results:** General and neurological examinations as well as conventional MRIs were unremarkable. Neuropsychological assessments showed moderate anxiety and depression in one patient and minimal in others. Unlike three patients, maximal and off-headache TCD evaluation in one revealed increased middle cerebral artery blood flow velocity, at the maximal pain area. Although with no seizure history, the same patient's EEG showed paroxysmal epileptic discharges during maximal headache intensity, respectively. Group level activation map fMRI showed activated classical pain matrix regions upon headache bouts (periaqueductal grey, substantia nigra and raphe nucleus), and markedly bilateral occipital lobes activation.

**Conclusion:** The EEG changes were of note. Furthermore, the increased BOLD signals in areas outside the classical pain matrix (i.e. occipital lobes) during maximal headaches may suggest that activation of these areas can be linked to the increased neural activity or visual cortex hyperexcitability in response to visual stimuli. These findings can introduce new perspective towards more in-depth functional imaging studies in headaches of poorly understood pathophysiology.

## Introduction

When headache is frequent, chronic and long-lasting, we possibly encounter a complex although non critical issue.<sup>1</sup> Almost all recurrent episodic headaches can potentially be turned into chronic type.<sup>2</sup> Chronic daily headache (CDH), described as a primary headache occurring at least 15 days per month for more than 3 months, is perceived as a worldwide problem reported by roughly 4% of the population.<sup>3</sup> Advances in biomedical technologies such as functional neuro-imaging may offer hope for a more in-depth studies aiming to explain CDH etiology as well as its relation with psychosocial and environmental factors.<sup>3,4</sup> CDH is not a diagnosis but an entity comprising various disorders resembling primary and secondary headaches. As all organic etiologies of chronic headache must be considered, the diagnosis array comprising tension type headache, migraine, cluster headache, hemicrania continua, medication overuse headache (i.e. following acute phase medications use more than 10 days per month for three months) should be sought.<sup>5,6</sup>

CDH pathogenesis is distinct from episodic headaches that makes further investigations necessary. One of the diagnostic criteria for CDH is normal laboratory assessments and conventional imaging such as computed tomography (CT) scan and magnetic resonance imaging (MRI).<sup>7</sup> More recent imaging techniques using the tissue paramagnetic properties can reveal magnetic, biochemical and physiologic tissue characteristics even before anatomical changes. This can help understanding the pathophysiology of diseases which have remained unexplained so far. Using diffusion, perfusion and BOLD (blood oxygen level dependent) MRI, we can detect the regional functions of the brain.<sup>1,6,8-10</sup> As a distinct brain regional function increases, blood flow to that region peaks, thus deoxy hemoglobin / oxyhemoglobin ratio declines. This effect causes signal changes in functional MRI (fMRI). Some fMRI investigations on different headache types including CDH have indicated enhanced signal intensity in specific brain regions.<sup>1,6,11</sup>

We hypothesized that there should be some specific regions within or outside the pain matrix of the brain<sup>12</sup> governing this chronic type headache. These areas may possibly subject to dysfunction in severe headache episodes.<sup>11,12</sup> Given this, we comprehensively assessed four CDH patients upon their self-rated most severe headache episodes. By means of clinical (history, physical examination and neuropsychological assessments) and paraclinical [electroencephalogram (EEG), transcranial Doppler (TCD) and fMRI] evaluations, we aimed to arrive at possible culprits for their severe, persisting and intractable headaches. Since the headache pattern varies from patient to patient and cross-cases comparisons does not seem to be possible,

we compared each patient's data with his/her own off-headache condition. The purpose of this investigational case series was to use fMRI and other findings to possibly define the partial pathophysiological mechanism(s) involved in CDH.

## Materials and Methods

This investigational case series recruited four patients (three females and one male;  $47.7 \pm 10.5$  years old) who had been suffering from CDH for more than 3 years. These patients, who fulfilled the international classification of headache disorders' criteria for CDH<sup>3</sup>, were interviewed and got an informed consent signed before entering the investigation. A focused history was taken and systemic and neurological examinations were performed on each patient. Neuropsychological assessments were done using the validated Farsi versions of Addenbrooke's neurocognitive battery (ACE),<sup>13</sup> Beck's depression<sup>14</sup> and anxiety<sup>15</sup> inventories (BDI-II, BAI). Furthermore, sleep quality indices and excessive daytime sleepiness assessment were done using the validated Farsi version of the Pittsburgh Sleep Quality Index (PSQI)<sup>16</sup> and the Epworth Sleepiness Scale (ESS)<sup>17</sup>, respectively.

### *Experiment 1: Baseline neurological evaluation*

Initially, all patients underwent conventional brain MR Imaging to rule out any possible structural brain lesions. Routine lab data were also collected. Patients were trained to report the severity of their headache episodes using the visual analogue scale score (VAS).<sup>18</sup> Upon self-rated VAS score of 0-3/10 which represented no or minimal headache, patients underwent EEG, TCD and fMRI studies. The second series of the same assessments were done when patients reported the worst experienced headache over the past 30 days; self-scored 8-10/10 on VAS.

### *Experiment 2: Neuropsychological assessments*

All neuropsychological assessment questionnaires were in local language, having been validated for internal consistency and test-retest reliability was confirmed in published literature.<sup>13-17</sup> The scoring data were presented and interpreted according to the questionnaires' manuals.

### *Experiment 3: TCD evaluation*

We did TCD examination in all cases during their maximal and minimal (or no) headache episodes. Transcranial Doppler insonation of brain vessels were done, using a 2 MHz probe through temporal, transorbital and transforaminal windows to assess the blood flow velocity in anterior, middle and posterior cerebral, ophthalmic and vertebrobasilar arteries. The common, internal and external carotid arteries were insonated using a 4 MHz probe. The TCD findings for the four cases are summarized in table 1.

**Table 1.** Transcranial Doppler Findings

		MCA	ACA	PCA	Ophth	Siph	ICA	VA	Bas
Case 1 (P. K.)									
Without headache	Right	43	44	26	24	41	49	33	
	Left	44	38	24	23	50	49	30	30
With headache	Right	47	43	29	27	43	49	33	
	Left	64	46	26	25	55	53	32	35
Case 2 (S. S.)									
Without headache	Right	73	58	41	21	55	54	38	
	Left	70	48	38	21	58	50	52	62
With headache	Right	76	54	45	22	56	63	49	
	Left	63	71	46	17	56	56	60	65
Case 3 (A. J.)									
Without headache	Right	64	58	40	21	62	49	37	
	Left	65	61	31	19	64	47	38	56
With headache	Right	54	49	23	23	60	41	33	
	Left	57	50	27	20	63	35	35	48
Case 4 (M. K.)									
Without headache	Right	60	44	31	23	43	33	45	
	Left	66	55	34	21	43	43	32	33
With headache	Right	42	59	34	23	39	39	36	
	Left	48	46	31	25	41	48	37	34

The mean arterial flow velocities in studied vessels are summarized. All values are in cm/s. MCA: Middle Cerebral Artery, ACA: Anterior Cerebral Artery, PCA: Posterior Cerebral Artery, Ophth: Ophthalmic artery, Siph: Carotid Siphon, ICA: Internal carotid Artery, VA: Vertebral Artery, Bas: Basilar Artery.

Case 1 study revealed a diminished mean blood flow velocity bilaterally in MCA and PCA during off-headache evaluation. It however, showed an increase in mean blood flow velocity in left MCA upon maximal intensity headache by 50%. Other cases' TCD study showed no significant differences in values obtained during off-headache and maximal headache evaluations.

#### **Experiment 4: Electrophysiology assessments**

In this experiment, EEG findings in and outside the headache bouts were compared in terms of possible presence of abnormal features.

#### **Experiment 5: Functional MRI to assess brain anatomical points possibly engaged in pain related neural activations**

We used fMRI recorded BOLD response during patients' maximal headache and off or minimal headache episodes based on the self-scored VAS. For the maximal headache scans, patients were scanned within 4 hours since they reported the maximal intensity headache. Imaging was performed using a 1.5 T Siemens scanner with a quadrature head coil. A gradient echo planar imaging (EPI) sequence with time echo to time repetition ration of 30/2500 was conducted. By this, 74 volumes were captured upon each scan. Functional scans comprised 33 slices (3.5 mm thick with a 3.5mm in-plane resolution i.e. 64 x 64) in oblique orientation, matching the brain stem axis. The obtained functional data in either maximal or minimal (or no) headache states were then analyzed using scripts in FMRIB's Software Library (FSL, <http://www.fmrib.ox.ac.uk/fsl>). None of the subjects demonstrated signs of gross movement (>1 voxel) during the functional scans. Captured volumes were spatially smoothed with a 5 mm full-width at half maximum filter.<sup>19,20</sup>

The analyzed data were used for a group-level

activation map, employing the mixed-level model. The difference in brain activation level between maximal and minimal (or no) headache episode signals was done through a voxel-wise paired t-test. Significant voxels were identified within the regions of interest showing BOLD activity. The fMRI shown activated brain regions during maximal or minimal (or no) intensity headaches were then co-registered with the anatomical images using FMRIB's Linear Image Registration tool to identify which brain anatomical points has possibly engaged in pain related neural activations.<sup>20</sup>

#### **Cases and the corresponding core findings**

##### **Case 1**

P. K., a 52-year-old married female, mother of two children, with MA educational level had suffered from chronic headache since 20 years ago. For many years, the headaches were mild to moderate with long intervals. Following an emotional stressor, she started to experience regular and more intense headaches since 8 years ago and turned to a case of CDH since 3 years prior to the current presentation. She mainly complained of nocturnal headaches aggravated by intense emotions. Headaches were most often unilateral on the left side. Upon attacks, she became nauseated and sensitive to photic or acoustic stimuli. The headache was refractory to various analgesics. The patient's past medical history

was not significant. There was a positive family history of intense headache in her mother and sister. She had no medication history except analgesics. Likewise, she had received no prophylactic regimen for the headaches.

Neurological examinations and conventional MRI were normal. On psychological assessments, she had normal cognitive performance status (MMSE and ACE); however, BAI, BDI-II and PSQI scales showed that she had moderate anxiety and depression as well as poor global sleep quality. The psychological assessment results of all four cases are outlined in table 2.

Off-headache EEG demonstrated scattered sharp wave activity. The repeated EEG evaluation during the maximal headache episode, turned out to reveal generalized paroxysmal epileptiform activity. Figure 1 illustrates her EEG patterns during off-headache and maximal headache episodes.

TCD findings in headache-free evaluation indicated a diminished mean blood flow velocity in bilateral middle and posterior cerebral arteries (MCA and PCA). However, it showed an increase in mean blood flow velocity in left MCA upon maximal intensity headache (the headache site, by 50%). Routine lab data was within normal limits. After all, the clinical impression was chronic migraine headache.

#### Case 2

S. S., a 32-year-old married female, no children, with MSc educational level who had the complaint of 'on and off' mild to moderate headache for many years. Her more intense and frequent headache attacks started 5 years ago and had been a case of CDH (over 15 days per month headache) over the past 3 years. Her headache bouts were almost always very intense (rated 8-10/10 in VAS) especially when she was physically tired and was partially alleviated by sleep. She reported a unilateral (mainly right hemispheric) throbbing

headache with no concurrent nausea, vomiting, photophobia and phonophobia during the episodes. Presence of headache did not follow a diurnal pattern. The patient neither had a significant past medical nor a family history of headache. The medication and substance use history was negative except for simple analgesics in routine basis. General and neurological physical examinations, laboratory workups and brain MRI were within normal limits. Her psychological assessments demonstrated normal cognitive functioning (MMSE and ACE); however, a minimal anxiety and depression was detected based on BAI and BDI-II scales, respectively. PSQI showed an appropriate sleep quality (Table 2).

EEG and TCD studies upon maximal and headache-free episodes were unremarkable, showing no quantitative and qualitative differences in both states as compared to each other. The clinical impression for this case was again, chronic migraine headache.

#### Case 3

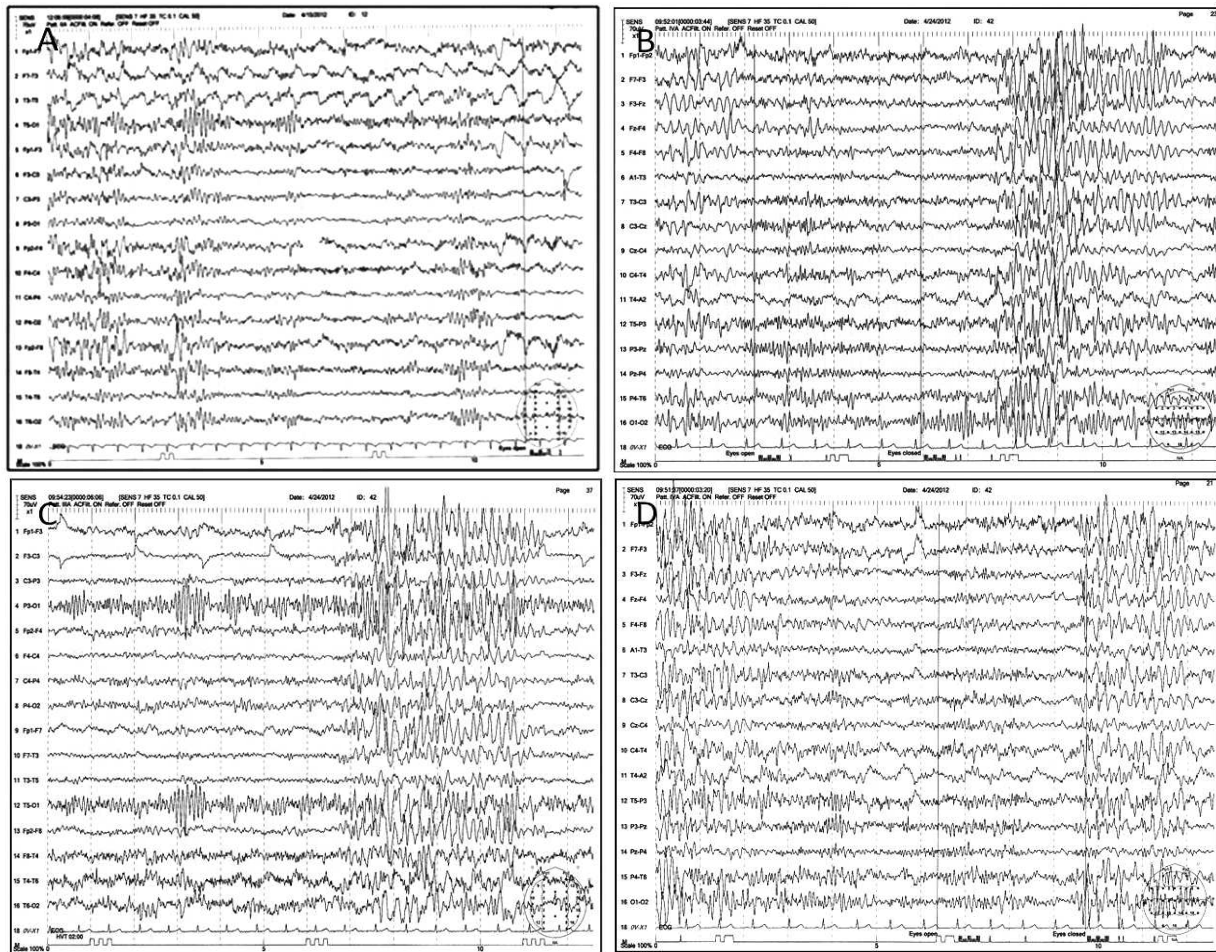
A. J. was a 53-year-old female, widow, with no children, and illiterate. She revealed the history of quite often headaches responsive to analgesics since 5 years ago. After the loss of her husband (three years ago) she started to have chronic headache which affected her for more than 15 days per month. The headache was mainly bilateral and retro-orbital and if unilateral, was in right side involving occipital and upper cervical regions. The pain had a constrictive nature however not accompanied by nausea, vomiting, photophobia and phonophobia. The headache was aggravated during emotional stresses and alleviated by rest. In the past medical history, she had infertility. She used to take non-steroidal anti-inflammatory drugs (NSAIDs) for her chronic headache, which was not any more effective

**Table 2.** The psychological assessments of four cases

Psychological Testing	Case 1 (P.K.)	Case 2 (S.S.)	Case 3 (A.J.)	Case 4 (M.K.)
Mini-mental state examination, MMSE (Max: 30)	28	29	24	29
Addenbrooke's Cognitive examination, ACE-P (Max: 100)	89	95	65	86
Subscales				
Attention and orientation (Max: 18)	17	18	11	17
Memory (Max: 26)	22	26	19	20
Verbal fluency (Max: 14)	9	11	7	7
Language (Max: 26)	22	26	17	20
Visuo-spatial ability (Max: 16)	16	14	8	15
Beck's anxiety inventory score (BAI)	21*	2 <sup>□</sup>	6 <sup>□</sup>	6 <sup>□</sup>
Beck's depression inventory (BDI-II)	31**	4 <sup>β</sup>	14 <sup>μ</sup>	9 <sup>β</sup>
Pittsburg Sleep Quality Index (PSQI)	14 <sup>§</sup>	4 <sup>¥</sup>	11 <sup>μμ</sup>	15 <sup>§</sup>
Epworth sleepiness Scale (ESS)	14 <sup>¶</sup>	5 <sup>¶¶</sup>	9 <sup>¶</sup>	15 <sup>¶</sup>

Max: Maximum score of each scale

□: Minimal anxiety, β: Minimal depression, \*: Moderate anxiety, μ: Mild depression, \*\*: Severe depression, §: Poor sleep quality, ¶: Excessive sleepiness, ¥: Proper sleep quality and ¶¶: No excessive sleepiness, μ: Mild depression, μμ: moderate sleep quality



**Figure 1.** Electroencephalogram (EEG) study epochs belonging to case 1

Although with no history of seizure and being awake and conscious during the EEG recording, she demonstrated scattered sharp waves during off-headache EEG assessment (A) as well as paroxysmal generalized epileptiform activity during maximal headache EEG study (B, C and D).

Moreover, the patient had not been administered prophylactic regimens for the headaches. Family history was not significant. Apart from the body mass index of 28, general physical examination was normal. Neurological examination, lab data and brain MRI were also within normal limits. Psychological evaluations (despite the illiteracy issue) showed a normal cognitive profile (MMSE and ACE). BAI and BDI-II scales showed a minimal anxiety and depression. Her sleep quality was impaired based on PSQI (Table 2). EEG and TCD evaluations in maximal and headache-free episodes were normal. Lab data were inconclusive. The clinical impression we had, was the chronic tension type headache.

#### Case 4

M. K. was a 54-year-old male, married, father of two children and with educational level of PhD. He reported mild transient headache since young adulthood, becoming a known case of migraine when he was 26 years old. He used to take ergotamine-C upon headache during those years. Due to severity and frequency of episodes, he was given prophylactic

regimens since the age of 40; however, became refractory in a matter of few years. He was labeled as CDH since 5 years ago. The headache had been intrusive in over 20 days per month lasting 15 hours per day in average. Headaches are mostly bilateral, causing photophobia and phonophobia and accompanied by nausea and vomiting in severe instances. The headache timing did not follow a distinct pattern; however, was more intense at nights. Pain was partly alleviated by sleep. His past medical history was negative. He revealed a family history of migraine in her mother. Over the past few years, he experienced various medications including prophylactic tetracyclic antidepressant, benzodiazepines, antiepileptic, beta blockers and lithium carbonate to all which he failed response. He had recently been taking sumatriptan and ergotamine as abortive medication upon headache episodes, with a very modest response. His general and neurologic examinations as well as the conventional brain MRI with and without contrast were normal. His psychological assessments indicated a normal neuro-cognitive state (MMSE and ACE); however, with a

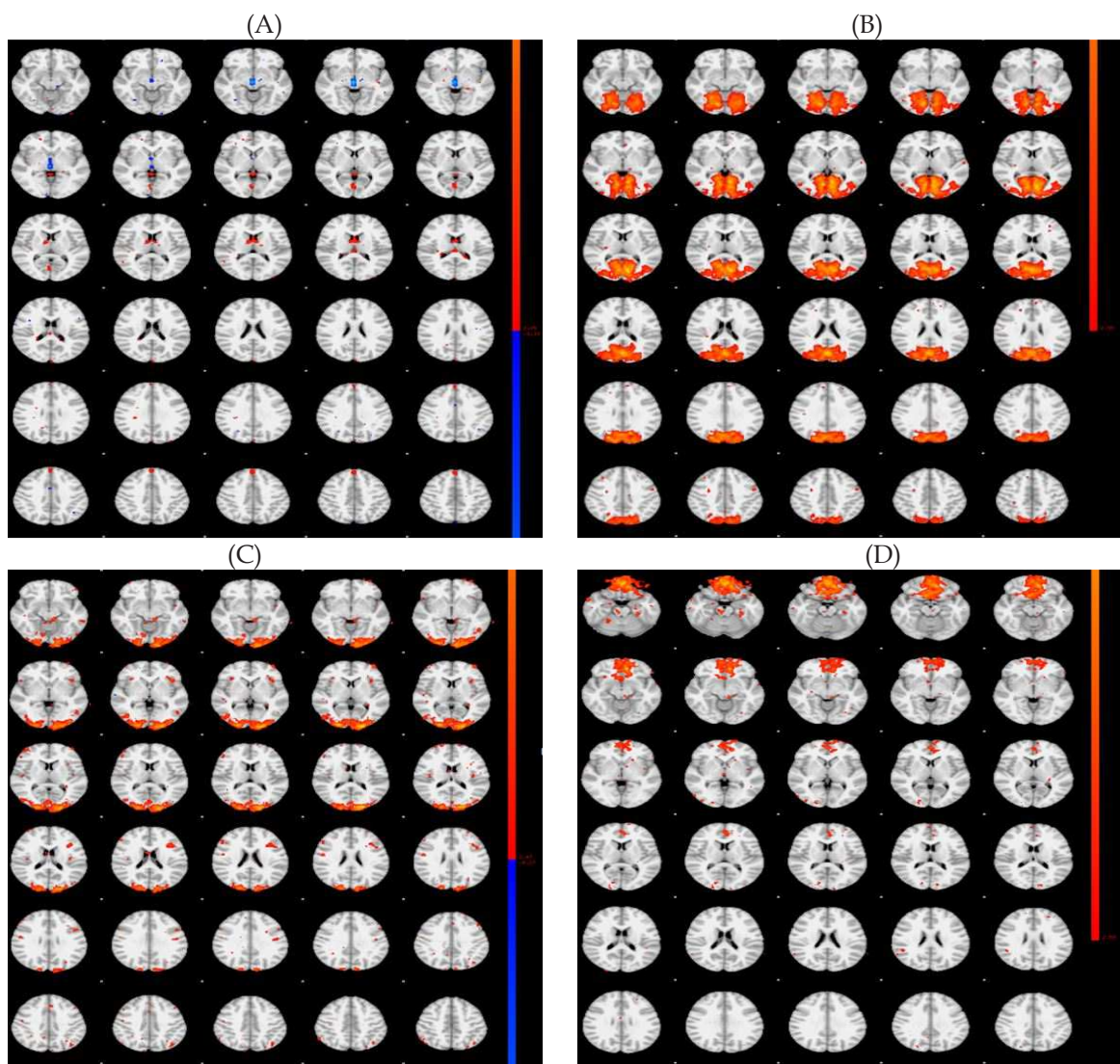
minimal anxiety and depression based on BAI and BDI-II. His sleep quality was evaluated poor, as per PSQI (Table 2).

He had no significant findings during maximal and minimal headache EEG and TCD evaluations. After all assessments, our impression was medication overuse headache (MOH). His acute phase medications were discontinued and interestingly, after many years, his headache turned into less intense with an episodic pattern, once or twice a week.

#### *The group-level fMRI activation map*

As described in experiment 4, fMRI data in group-level was acquired through BOLD signal acquisition and FSL

based analysis. Head motion was corrected, if any. Detailed data analysis per protocol, indicated a difference in brain activation level between maximal and minimal (or no) headache episode signals. There were areas not active in headache-free state, however active during maximal headache. This was documented by a voxel-wise paired t-test. We then co-registered the fMRI with the anatomical images through FMRIB's Linear Image Registration tool. In our group-level analysis, bilateral occipital and to the lesser extent frontal pole regions were active during headache but not active in headache free (or minimal headache) states. The above findings are shown in figure 2.



**Figure 2.** fMRI group level activation map for BOLD response during off or minimally presented headache based on the self scored VAS using (A) and during maximal headache episodes (B, C and D). Functional data were analyzed using scripts in FMRIB's Software Library (FSL). The analyzed data were used for a group-level activation map, through the mixed-level model. The voxel wise paired t-test was employed to distinguish possible differences in activation during off-headache and maximal headache state fMRI assessment. During headache bouts, group-level activation map fMRI, revealed a markedly increased BOLD signal in bilateral occipital regions (B, C) and also modest fronto-polar BOLD signal increase(D). These changes were not seen in off-headache conditions (A).

## Discussion

Headache is one of the most important health problems in our community.<sup>21,22</sup> Among the different types of prevalent headaches, CDH or chronic daily headache as a persistent headache not responding to treatments, brings along concern and discomfort both for patients and physicians dealing with the problem.<sup>4,23</sup> Most of the studies employing functional neuro-imaging have considered migraine headaches<sup>1,4,5,9,10,23</sup> and CDH as specific types of headache that have minimally been investigated in-depth.

To the best of knowledge, studies on patients with CDH having simultaneously performed an array of diagnostic measures such as EEG, TCD, and fMRI are scant. An EEG, TCD and SPECT investigation done in one patient with migraine, reported a decrease in TCD flow velocity in aura phase and increased flow velocity upon bouts of headaches.<sup>24</sup> In this study, when patient was experiencing aura, EEG revealed slow waves in bilateral occipital regions, and SPECT demonstrated right parieto-occipital hypo perfusion. All these phenomena reversed upon relief of the headache.<sup>24,25</sup>

Other studies which used EEG at rest and during the headache attacks indicated that, upon headache there were evident changes in frequency and amplitude of alpha bands as well as presence of diffused theta and delta waves in the brain; however, no report has revealed presence of epileptiform activity upon headache attacks.<sup>26,27</sup> This is in contrast to our findings. Upon EEG evaluation, our 'case 1' showed generalized paroxysmal epileptiform activity during maximal headache. This patient had no history of epilepsy and despite epileptiform activity during maximal headache EEG evaluation, remained fully alert and oriented to her surroundings. She also did not show such EEG presentations when the assessment was repeated off-headache.

Vernieri et al. studied 12 migraine headache patients using TCD. Patients with unilateral headache, showed cerebrovascular reactivity to the opposite side upon headache as compared to off-headache condition.<sup>28</sup> In another TCD study on children with migraine headache, 23 out of 62 cases showed increased mean arterial flow velocity.<sup>29</sup> Likewise, we observed an increase in flow velocity of left MCA (the point where the patient suffered maximal headache intensity although the headache was generalized). The flow velocity increased from 44 cm/s to 64 cm/s which were a significant rise upon headache. We however, did not observe any significant changes in cerebral arterial mean flow velocity in our other cases upon headache as compared to off-headache conditions.

Studies assessing patients with various types of headache with functional neuro-imaging (fMRI),

demonstrated controversial results. According to Chiapparini and his associates,<sup>9</sup> cases with migraine and medication overuse headache, revealed a decreased activity and hypo metabolism in cortical areas affected during pain sensation, including the periaqueductal gray (PAG) and the substantia nigra (SN). These fMRI changes reversed when the responsible medications were stopped. The fMRI included investigation by Grazi and colleagues<sup>30</sup> indicated a diminished activity in right supramarginal and parietal cortices in patients with medication overuse headache. These changes returned to normal 6 month after discontinuation of respective medications. Arne May et al.<sup>6,11</sup> reported that, during migraine attacks there are some hyper activated regions in the brainstem; while during bouts of trigeminal neuralgia some hypothalamic sub-regions get activated. Moreover, they reported that during migraine headache, cerebral blood flow gets diminished in posterior parts of the brain; however, BOLD signals enhance in occipital regions.<sup>11</sup> These findings are partly in line with what we observed during our fMRI assessment. Cao et al. similarly documented that during aura phase of migraine (induced by photic stimulation), the neural activity in occipital lobes declines whereas upon headache phase, occipital lobes become hyper-oxygenated.<sup>10</sup> In Aurora et al. study during which they thoroughly investigated a CDH patient possibly induced with ergotamine overuse, it was found that upon maximal episodes of these headaches red nucleus and substantia nigra were hyper activated while these finding disappeared when the CDH turned into episodic migraine following discontinuation of the culprit drugs.<sup>31</sup>

We performed an fMRI assessment on 4 patients fulfilling the criteria for CDH. Functional MRIs were taken upon patients' self-rated (VAS) maximal intensity headache episodes and off-headache conditions. Each patient had at least 2 functional images at given conditions. During headache bouts and in group-level activation map fMRI, we observed an increased BOLD signal in bilateral occipital regions. These changes however were not seen in off-headache conditions. Since occipital region is literally outside the classical pain pathway,<sup>12</sup> its activation turned to be of special note to us only during the maximal headache.

Since all our patients were reporting a generalized headache while under fMRI scanner and none of them had even a minimal complaint of a localized occipital headache, activation of occipital area might at least partly be attributed to hyper-excitability of this region to the peripheral visual stimuli during headache. This question per se, can be a topic for a separate in-depth investigation.

## Conclusion

Despite the current investigation's findings and similar reports, the etiopathophysiological features of the refractory headaches such as CDH have remained unclear or just partly understood. As far as we know, this has been the first of a kind fMRI investigation with regard to headache, carried out in Iran. Our core findings, such as 1) presence of epileptiform activity,

2) increased mean cerebral arterial flow velocity, and 3) enhanced occipital lobes' BOLD signals upon headache bouts in CDH, suggest the necessity to conduct more comprehensive and larger studies in this field. These efforts are expected to provide insights regarding the pathophysiology of such debilitating headaches, offering hopes for more efficient treatments in the future.

## References

1. May A. A review of diagnostic and functional imaging in headache. *J Headache Pain*. 2006; 7(4): 174-84.
2. Farooq K, Williams P. Headache and chronic facial pain. *Contin Educ Anaesth Crit Care Pain*. 2008; 8(4): 138-42.
3. Aurora SK. Chronic daily headache: recent insights from functional imaging. *J Headache Pain*. 2004; 5(3): 177-80.
4. Laszlo M. Neuroimaging of headaches: continuum. *Neuroimaging*. 2008; 14(4).
5. Matharu MS, Goadsby PJ. Functional brain imaging in hemicrania continua: implications for nosology and pathophysiology. *Curr Pain Headache Rep*. 2005; 9(4): 281-8.
6. May A, Ashburner J, Buchel C, et al. Correlation between structural and functional changes in brain in an idiopathic headache syndrome. *Nat Med*. 1999; 5(7): 836-8.
7. Maizels M. The patient with daily headaches. *Am Fam Physician*. 2004; 70(12): 2299-306.
8. Micieli G, Bosone D, Marcheselli S, et al. Cerebral hemodynamics in primary headaches: the transcranial Doppler experience. *Cephalalgia*. 1998; 18(Suppl 21): 17-22.
9. Chiapparini L, Grazi L, Ferraro S, et al. Functional-MRI evaluation of pain processing in chronic migraine with medication overuse. *Neurol Sci*. 2009; 30(Suppl 1): S71-S74.
10. Cao Y, Welch KM, Aurora S, et al. Functional MRI-BOLD of visually triggered headache in patients with migraine. *Arch Neurol*. 1999; 56(5): 548-54.
11. May A. Headache: lessons learned from functional imaging. *Br Med Bull*. 2003; 65: 223-34.
12. Rocca MA, Valsasina P, Absinta M, et al. Central nervous system dysregulation extends beyond the pain-matrix network in cluster headache. *Cephalalgia*. 2010; 30(11): 1383-91.
13. Pouretamad HR, Khatibi A, Ganjavi A, et al. Validation of Addenbrooke's cognitive examination (ACE) in a Persian-speaking population. *Dement Geriatr Cogn Disord*. 2009; 28(4): 343-7.
14. Ghassemzadeh H, Mojtabai R, Karamghadiri N, et al. Psychometric properties of a Persian-language version of the Beck Depression Inventory-Second edition: BDI-II-PERSIAN. *Depress Anxiety*. 2005; 21(4): 185-92.
15. Kaviani H, Mousavi AS. Psychometric properties of the Persian version of Beck Anxiety Inventory (BAI). *Tehran Univ Med J*. 2008; 65(2): 136-40. [In Persian].
16. Sadeghniaat HK, Montazeri A, Khajeh MA, et al. The Epworth Sleepiness Scale: translation and validation study of the Iranian version. *Sleep Breath*. 2013; 17(1): 419-26.
17. Farrahi MJ, Nakhaee N, Sheibani V, et al. Reliability and validity of the Persian version of the Pittsburgh Sleep Quality Index (PSQI-P). *Sleep Breath*. 2012; 16(1): 79-82.
18. Wewers ME, Lowe NK. A critical review of visual analogue scales in the measurement of clinical phenomena. *Res Nurs Health*. 1990; 13(4): 227-36.
19. Woolrich MW, Jbabdi S, Patenaude B, et al. Bayesian analysis of neuroimaging data in FSL. *Neuroimage*. 2009; 45(1 Suppl): S173-S186.
20. Smith SM, Jenkinson M, Woolrich MW, et al. Advances in functional and structural MR image analysis and implementation as FSL. *Neuroimage*. 2004; 23(Suppl 1): S208-S219.
21. Fallahzadeh H, Alihaydari M. Prevalence of migraine and tension-type headache among school children in Yazd, Iran. *J Pediatr Neurosci*. 2011; 6(2): 106-9.
22. Ayatollahi SM, Moradi F, Ayatollahi SA. Prevalences of migraine and tension-type headache in adolescent girls of Shiraz (Southern Iran). *Headache*. 2002; 42(4): 287-90.
23. Chiapparini L, Ferraro S, Grazi L, et al. Neuroimaging in chronic migraine. *Neurol Sci*. 2010; 31(Suppl 1): S19-S22.
24. La Spina I, Frazzitta G, Grampa G, et al. Transcranial Doppler, EEG and SPECT findings of a focal reduction of cerebral blood during the aura phase in migraine. *Journal of the Neurological Sciences*. 1997; 150: S34-S34.
25. Buchgreitz L, Egsgaard LL, Jensen R, et al. Abnormal pain processing in chronic tension-type headache: a high-density EEG brain mapping study. *Brain*. 2008; 131(Pt 12): 3232-8.
26. Bjork MH, Stovner LJ, Nilsen BM, et al. The occipital alpha rhythm related to the "migraine cycle" and headache burden: a blinded, controlled longitudinal study. *Clin Neurophysiol*. 2009; 120(3): 464-71.
27. Bjork MH, Stovner LJ, Engstrom M, et al. Interictal quantitative EEG in migraine: a blinded controlled study. *J Headache Pain*. 2009; 10(5): 331-9.
28. Vernieri F, Tibuzzi F, Pasqualetti P, et al. Increased cerebral vasomotor reactivity in migraine with aura: an autoregulation disorder? A transcranial Doppler and near-infrared spectroscopy study. *Cephalalgia*. 2008; 28(7): 689-95.
29. Boasso LE, Fischer AQ. Cerebral vasospasm in childhood migraine during the intermigrainous period. *J Neuroimaging*. 2004; 14(2): 158-61.
30. Grazi L, Chiapparini L, Ferraro S, et al. Chronic migraine with medication overuse pre-post withdrawal of symptomatic medication: clinical results and FMRI correlations. *Headache*. 2010; 50(6): 998-1004.
31. Aurora SK, Barrodale P, Chronicle EP, et al. Cortical inhibition is reduced in chronic and episodic migraine and demonstrates a spectrum of illness. *Headache*. 2005; 45(5): 546-52.