

# Pantothenate kinase 2 mutation with eye-of-the-tiger sign on magnetic resonance imaging in three siblings

Mitra Ansari Dezfouli<sup>1</sup>, Elham Jaber<sup>1</sup>, Afagh Alavi<sup>1</sup>, Mohammad Rezvani<sup>2</sup>, Gholamali Shahidi<sup>3</sup>, Elahe Elahi<sup>1,4</sup>, Mohammad Rohani<sup>3</sup>

<sup>1</sup> School of Biology, College of Science, University of Tehran, Tehran, Iran

<sup>2</sup> Department of Neurology, Tehran University of Medical Sciences, Tehran, Iran

<sup>3</sup> Associate Professor, Department of Neurology, Tehran University of Medical Sciences, Tehran, Iran

<sup>4</sup> Professor, Department of Biotechnology, College of Science, University of Tehran, Tehran, Iran

## Keywords

Neurodegeneration, Brain Iron Accumulation, Pantothenate Kinase Associated Neurodegeneration, *PANK2* gene, Eye-of-the-Tiger sign

## Abstract

**Background:** Pantothenate kinase associated neurodegeneration (PKAN) is the most prevalent type of neurodegeneration with brain iron accumulation (NBIA) disorders characterized by extrapyramidal signs, and 'eye-of-the-tiger' on T2 brain magnetic resonance imaging (MRI) characterized by hypointensity in globus pallidus and a hyperintensity in its core. All PKAN patients have homozygous or compound heterozygous mutation in *PANK2* gene.

**Methods:** Three sibling patients were diagnosed based on clinical presentations especially extrapyramidal signs and brain MRI. The exons and flanking intronic sequences of *PANK2* were sequenced from DNA of leukocytes of the affected individuals.

**Results:** All patients were homozygous for c.C1069T, p.R357W in *PANK2* gene. This mutation is well conserved in the homologous protein of distally related species.

**Conclusion:** In the current study we identified three siblings affected with PKAN, all of them have mutations in

*PANK2* gene. In MRI of all patients with *PANK2* mutation eye-of-the-tiger sign was apparent.

## Introduction

Neurodegeneration with brain iron accumulation (NBIA) encompasses a group of rare neurodegenerative diseases characterized by relentlessly progressive extrapyramidal signs and iron accumulation in the brain usually in the globus pallidus.<sup>1,2</sup> The most prevalent form of NBIA is pantothenate kinase associated neurodegeneration (PKAN) also known as NBIA-1 which accounts for approximately half of the cases of NBIA.<sup>3</sup> This syndrome first described by Julius Hallervorden and Hugo Spatz in 1922;<sup>4</sup> however, their involvement with Nazi extermination politics lead to discredit them.<sup>5</sup> PKAN syndrome is characterized by autosomal recessive inheritance and the 'eye of the tiger' pattern of iron accumulation in the pallidum on T2 weighted magnetic resonance imaging (MRI) which is caused by iron deposition in the periphery (hypointensity) and necrosis on its core (hyperintensity).<sup>6,7</sup>

Clinical presentations include dystonia, dysarthria, and dysphasia. Dementia, severe mental retardation and severe movement disability may develop at later stages.<sup>8</sup> Rare clinical features include

rigidity, parkinsonism, choreoathetosis, seizures, optic atrophy, and pigmentary retinopathy. Based on age at onset and rate of progression, PKAN can be classified in two major forms. In the classic form of PKAN, onset is usually in the first decade of life. Visual impairment caused by optic atrophy or retinal degeneration have been described in some classical cases. Atypical PKAN is presented in the second decade of life with slow progression. Neurobehavioral disorders and seizure are common in atypical form.<sup>3</sup> All PKAN cases have mutation in *PANK2* gene located on 20p13.<sup>9</sup> *PANK2* encodes a mitochondrial pantothenate kinase which is the key regulatory enzyme in coenzyme A biosynthesis.<sup>10</sup>

In the current study, we report clinical and genetic findings of three PKAN patients from an Iranian family.

### Materials and Methods

Three sibling patients were diagnosed based on clinical presentations especially extrapyramidal signs and brain MRI findings of iron deposition in the globus pallidus. Details of clinical information and familial reputation (hisotor and information) were obtained and blood samples were collected from all patients after they had given informed consent. This research was performed in accordance with the Declaration of Helsinki and with approval of the ethics board of the University of Tehran. Participants or their guardians consented to participate after being informed of the nature of the research.

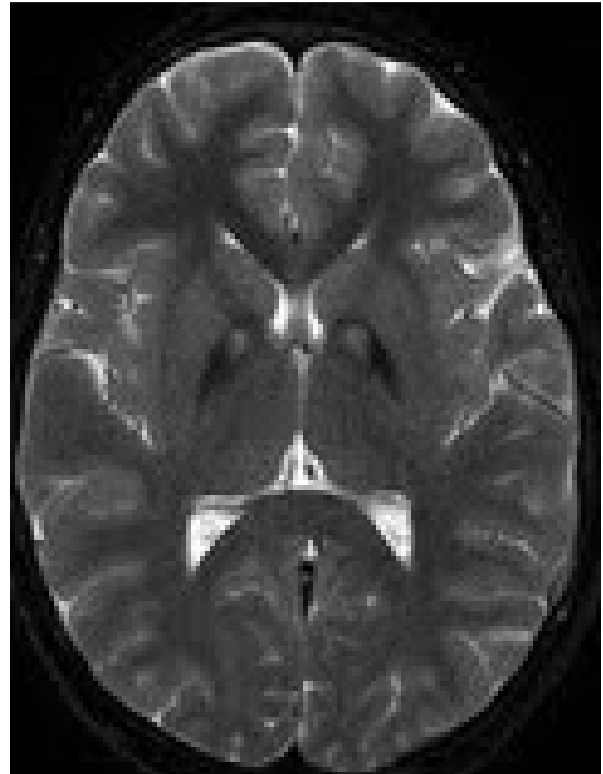
Primers were designed to amplify all eight exons. The exons and flanking intronic sequences of *PANK2* were amplified from DNA of leukocytes of the affected individuals. Amplicons were sequenced using the ABI Big Dye terminator chemistry and an ABI Prism 3700 instrument (Applied Biosystems, Foster City, CA). Sequences were analyzed with the Sequencher software (Gene Codes Corporation, Ann Arbor, MI). Obtained DNA sequences were compared to NG\_008131.1, NM\_024960.4, and NP\_705902.2. To determine the extent of amino acids conservation and the effect of DNA variations, we attained homologous proteins amino acid sequences of other species from ENSEMBL (<http://www.ensembl.org/index.html>) and aligned using the ClustalW2.0 software (<http://www.ebi.ac.uk/Tools/msa/clustalw2/>).

### Results

*PANK2* mutation was found in all three patients. Patients born to consanguineous family with no familial history of neurological disease and had homozygous mutations in *PANK2* gene. All these three patients had eye-of-the-tiger signs in T2 weighed brain MRI (Fig. 1).

Case I was 24 years old and suffered from progressive dystonia. He was normal at birth and during early developmental periods. At the age 10, he

complained from stiffness in his hands and 2 years later dystonia appeared in his upper limbs. Oromandibular dystonia caused problems in feeding. On exam he had severe dysarthria, dystonia (more prominent in hands and oromandibular region), Babinski sign and tremor in hands.



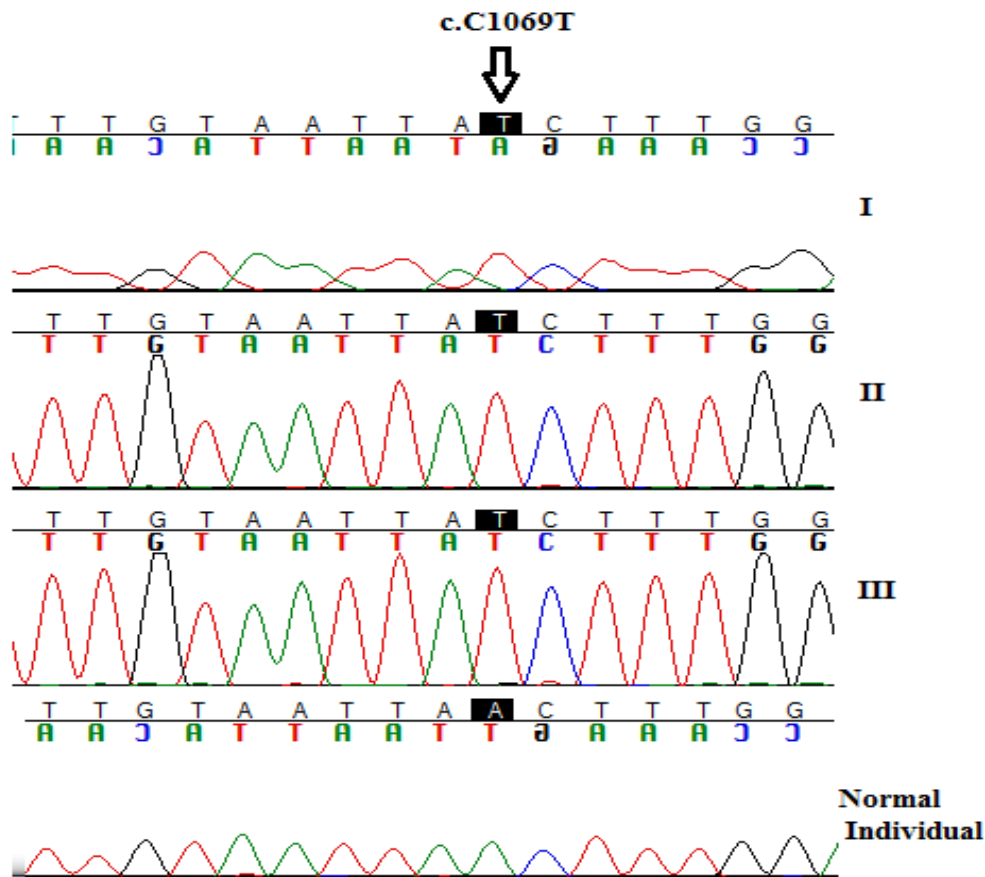
**Figure 1.** T2 weighted Brain magnetic resonance imaging of the patient I which shows a central hyperintensity within a surrounding area of hypointensity in globus pallidus (eye-of-the-tiger)

Case II was 18 years old girl and at the age of 10 her parents noticed stiffness and resting tremor in his upper and later in lower limbs and poor balance in usual movements and progressive difficulty in walking. She had severe hand dystonia and orolingual dystonia with recurrent lips and tongue biting. She could not walk without aid and was dependent for all daily living activities.

Case III was a 17 years old boy with normal early development. At the age 9, dystonia appeared in upper limbs. One year later, dysarthria, dysphasia and gait disturbance were added to the symptoms. Pursuit eye movements were fragmented and the saccades were slow.

All three patients were found to be homozygous for a mutation in exon 3 of the gene which resulted in a change of arginine to tryptophan at amino acid position 357 in pantothenate kinase2 enzyme (Fig. 2). This mutation have been previously reported by Zhou et al.<sup>9</sup> Importantly, this amino acid position is completely

conserved in homologous proteins (Table 1).



**Figure 2.** Chromatograms include mutations in each patient, the last one shows normal sequence

**Table 1.** Evolutionary conservation of amino acids affected by PANK2 Mutation in homologous proteins

Organisms	Transcript ID	p.R357W
homo sapiens (hPANK2)	ENST00000316562	SVGFNGRSQCYY
Pan troglodytes	ENSPTRT00000047902	SVGFNGRSQCYY
Nomascus leucogenys	ENSNLET00000009772	SVGFNGRSQCYY
Macaca mulatta	ENSMMUT00000028051	SVGFNGRSQCYY
Loxodonta africana	ENSLAFT00000003123	SVGFNGRSQCYY
Pongo abelii	ENSPPYT00000012548	SVGFNGRSQCYY
Bos taurus	ENSBTAT00000045589	SVGFNGRSECYY

## Discussion

There are evidences for the existence of an isoform of *PANK2* in mitochondrial in which the disease is caused by loss of function of this isoform.<sup>10,11</sup> The *PANK2* gene expresses abundantly in the brain.<sup>9</sup> It is predicted that the preprotein has 29 amino acid mitochondrial target sequence at the amino terminus.<sup>11</sup> Pantothenate kinase enzyme catalyzes the first and the most important rate controlling step of coenzyme A biosynthesis by phosphorylation of pantothenate (vitamin B5) to phosphopantothenate which is rapidly enter in the coenzyme A biosynthesis.<sup>12</sup> In its acetyl form, coenzyme A contributes in tricarboxylic acid cycle and fatty acids

beta oxidation as an acyl carrier. In the backward feedback coenzyme A and its thioester form can inhibit pantothenate kinase by binding to ATP binding site of the enzyme.<sup>13</sup>

The exact pathogenic mechanisms of the disease are unknown, but it has been suggested that stop production of phosphopantothenate causes accumulation of cysteine at the later stage of coenzyme A production and this surplus mass of cysteine can cause accumulation of excess iron in the brain and tissue damage by promoting oxidative stress.<sup>9,14</sup>

In this study, we identified three siblings affected with PKAN; all of them had mutations in *PANK2* gene. On brain MR imaging of all patients with

*PANK2* mutation "eye of the tiger" sign was apparent. However, it should be considered that other rare diseases like Karak syndrome and some cases with CO poisoning can show eye of the tiger sign.<sup>7, 15</sup> On the other hand, there are a few cases with mutation in *PANK2* and iron deposition in the globus pallidus without eye-of-the-tiger sign.<sup>16,17</sup> It has been suggested that sometimes with the disease progression and iron

deposition in the globus pallidus the central hyperintense signal and eye-of-the-tiger disappears.<sup>16</sup>

### Acknowledgments

This work was supported by Tehran University of Medical Sciences. We thank the patients for consenting to participate in this study.

### References

1. Gregory A, Hayflick SJ. Pantothenate Kinase-Associated Neurodegeneration. Orphanet Encyclopedia. 2004.
2. Gregory A, Polster BJ, Hayflick SJ. Clinical and genetic delineation of neurodegeneration with brain iron accumulation. *J Med Genet.* 2009; 46(2): 73-80.
3. Schneider SA, Hardy J, Bhatia KP. Syndromes of neurodegeneration with brain iron accumulation (NBIA): an update on clinical presentations, histological and genetic underpinnings, and treatment considerations. *Mov Disord.* 2012; 27(1): 42-53.
4. Hallervorden J, Spatz H. Eigenartige erkrankung im extrapyramidalen system mit besonderer beteiligung des globus pallidus und der substantia nigra. *Zeitschrift für die gesamte Neurologie und Psychiatrie.* 1922; 79(1): 254-302.
5. Shevell M. Racial hygiene, active euthanasia, and Julius Hallervorden. *Neurology.* 1992; 42(11): 2214-9.
6. Hayflick SJ, Westaway SK, Levinson B, et al. Genetic, clinical, and radiographic delineation of Hallervorden-Spatz syndrome. *N Engl J Med.* 2003; 348(1): 33-40.
7. Hayflick SJ, Hartman M, Coryell J, et al. Brain MRI in neurodegeneration with brain iron accumulation with and without *PANK2* mutations. *AJNR Am J Neuroradiol.* 2006; 27(6): 1230-3.
8. Hartig MB, Hortnagel K, Garavaglia B, et al. Genotypic and phenotypic spectrum of *PANK2* mutations in patients with neurodegeneration with brain iron accumulation. *Ann Neurol.* 2006; 59(2): 248-56.
9. Zhou B, Westaway SK, Levinson B, et al. A novel pantothenate kinase gene (*PANK2*) is defective in Hallervorden-Spatz syndrome. *Nat Genet.* 2001; 28(4): 345-9.
10. Hortnagel K, Prokisch H, Meitinger T. An isoform of h*PANK2*, deficient in pantothenate kinase-associated neurodegeneration, localizes to mitochondria. *Hum Mol Genet.* 2003; 12(3): 321-7.
11. Johnson MA, Kuo YM, Westaway SK, et al. Mitochondrial localization of human *PANK2* and hypotheses of secondary iron accumulation in pantothenate kinase-associated neurodegeneration. *Ann N Y Acad Sci.* 2004; 1012: 282-98.
12. Rock CO, Calder RB, Karim MA, et al. Pantothenate kinase regulation of the intracellular concentration of coenzyme A. *J Biol Chem.* 2000; 275(2): 1377-83.
13. Leonardi R, Zhang YM, Rock CO, et al. Coenzyme A: back in action. *Prog Lipid Res.* 2005; 44(2-3): 125-53.
14. Rouault TA. Iron on the brain. *Nat Genet.* 2001; 28(4): 299-300.
15. Mubaidin A, Roberts E, Hampshire D, et al. Karak syndrome: a novel degenerative disorder of the basal ganglia and cerebellum. *J Med Genet.* 2003; 40(7): 543-6.
16. Delgado RF, Sanchez PR, Speckter H, et al. Missense *PANK2* mutation without "eye of the tiger" sign: MR findings in a large group of patients with pantothenate kinase-associated neurodegeneration (PKAN). *J Magn Reson Imaging.* 2012; 35(4): 788-94.
17. Zolkipli Z, Dahmouh H, Saunders DE, et al. Pantothenate kinase 2 mutation with classic pantothenate-kinase-associated neurodegeneration without 'eye-of-the-tiger' sign on MRI in a pair of siblings. *Pediatr Radiol.* 2006; 36(8): 884-6.