

Transient unilateral oculomotor palsy in idiopathic intracranial hypertension: An interesting case

Received: 10 Dec. 2019
Accepted: 07 Feb. 2020

Zahra Karimi¹, Nazila Malekian¹, Siamak Abdi²

¹ Department of Neurology, Shariati Hospital, Tehran University of Medical Sciences, Tehran, Iran

² Iranian Center of Neurological Research, Neuroscience Institute, Tehran University of Medical Sciences, Tehran, Iran

Keywords

Intracranial Hypertension; Oculomotor Paralysis;
Chronic Kidney Failure

Idiopathic intracranial hypertension (IIH) is defined as elevated intracranial pressure (ICP) without a space-occupying lesion.¹ The clinical presentation is characterized primarily by headache, impaired vision, cranial nerve palsies, olfactory disturbances, cognitive deficits, and tinnitus.¹ We report a rare case with transient unilateral oculomotor palsy with the involvement of pupillary reflex due to IIH.

A 25-year-old woman with a past medical history of polyarteritis nodosa and end-stage renal disease presented to the emergency department with a one-month history of generalized headache and diplopia. Physical examination revealed bilateral papilledema with apparent normal extraocular movement. The next day, she developed complete left third cranial nerve palsy with the involvement of pupillary reflex. Brain magnetic resonance imaging (MRI) showed empty sella, bilateral optic nerve hydrops

and tortuosity, flattening of the posterior aspect of globes, and bilateral transverse sinus stenosis (Figure 1). Contrast MRI was not performed because of impaired renal function. Lumbar puncture (LP) revealed elevated ICP (28 cmH₂O) with normal cerebrospinal fluid (CSF) composition. The patient's symptoms resolved (including the disappearance of third nerve palsy) within one day after CSF drainage and administration of topiramate. Considering history, physical examination, MRI, and quick response to LP, diagnosis of IIH was made.

Currently, modified Dandy criteria are widely accepted for the diagnosis of IIH.² Papilledema, normal neurological examination except for cranial nerve disorders, brain MRI not explaining raised ICP, normal CSF study and measured high ICP compose the criteria. Abducens palsy is quite common and is known as a false localizing sign in patients with IIH.

How to cite this article: Karimi Z, Malekian N, Abdi S. Transient unilateral oculomotor palsy in idiopathic intracranial hypertension: An interesting case. *Curr J Neurol* 2020; 19(2): 96-7.

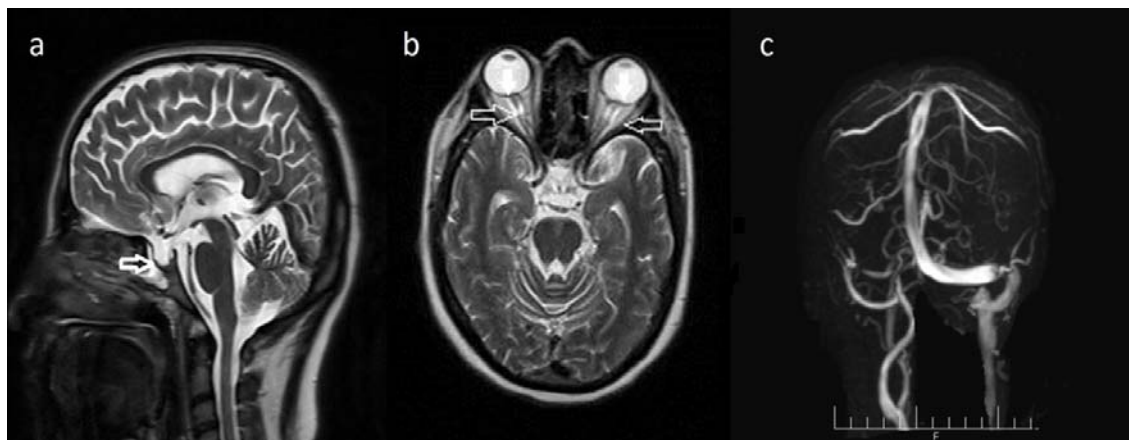


Figure 1. Cranial magnetic resonance imaging (MRI) of the patient. (a) Sagittal T2-weighted image through the midline shows a partial empty sella (arrow). (b) Axial T2-weighted image through the level of optic nerves shows prominent subarachnoid space (arrows), and protrusions of optic nerve heads (white arrow) suggestive of papilledema. (c) Magnetic resonance venography (MRV) without contrast shows smooth-bordered stenosis in distal portions of both transverse sinuses (arrow).

Oculomotor,³ trochlear,⁴ and facial⁵ nerves can be affected in these patients.

Conflict of Interests

The authors declare no conflict of interest in this

study.

Acknowledgments

None.

References

- Hoffmann J, May A. Update on pseudotumor cerebri (Idiopathic intracranial hypertension). *Neurol Int Open* 2017; 01(03): E224-E231.
- Friedman DI, Liu GT, Digre KB. Revised diagnostic criteria for the pseudotumor cerebri syndrome in adults and children. *Neurology* 2013; 81(13): 1159-65.
- Thapa R, Mukherjee S. Transient bilateral oculomotor palsy in pseudotumor cerebri. *J Child Neurol* 2008; 23(5): 580-1.
- Totuk OMG, Aldroubi N, Aykan U. A case of bilateral fourth nerve palsy associated with pseudotumor cerebri syndrome. *Arq Bras Ophthalmol* 2019; 82(4): 332-5.
- Capobianco DJ, Brazis PW, Cheshire WP. Idiopathic intracranial hypertension and seventh nerve palsy. *Headache* 1997; 37(5): 286-8.