



Transient global amnesia in a patient with painless spontaneous internal carotid artery dissection: An unusual but possible underlying cause

Received: 06 Dec. 2023
Accepted: 01 Feb. 2024

Francesco Natale¹, Riccardo Molinari², Noemi Mollo², Mirella Limatola², Lorenzo De Luca², Roberta Alfieri², Andrea Izzo³, Giovanni Cimmino^{4,5}

¹ Vanvitelli Cardiology Unit, Monaldi Hospital, Naples, Italy

² Department of Translational Medical Sciences, Section of Cardiology, University of Campania "Luigi Vanvitelli", Naples, Italy

³ Department of Precision Medicine, Section of Radiology, University of Campania "Luigi Vanvitelli", Naples, Italy

⁴ Department of Translational Medical Sciences, University of Campania "Luigi Vanvitelli", Naples, Italy

⁵ Cardiology Unit, Azienda Ospedaliera Universitaria Luigi Vanvitelli, Naples, Italy

Keywords

Internal Carotid Artery Dissection; Transient Global Amnesia; Carotid Arteries; Doppler Ultrasound

Transient global amnesia (TGA) is a condition that usually occurs in middle-aged and older individuals characterized by confusion, disorientation, reversible anterograde and retrograde amnesia of sudden onset that resolves spontaneously within 24 hours.¹ Precipitating factors might be sudden immersion in cold or hot water, extreme physical activity, invasive medical procedures, mild head trauma, emotional stress as well as migraine.¹ Annual incidence rate for this syndrome is about 5.2 to 10 per 100000 per year.¹ The pathophysiological mechanisms underlying this puzzling neurological syndrome are not completely clarified yet. Some studies support an

ischemic aetiology for TGA,² and cases of TGA following internal carotid artery (ICA)-stenting³ or aortic dissection with involvement of the supra-aortic branches are reported in literature;⁴ thus, supporting the hypothesis that a cause-effect relationship between ischemic pathologies of supra-aortic trunks and TGA might be present. Here, we presented a case of ICA dissection diagnosed by a Doppler ultrasound of carotid arteries in a patient presenting with TGA and asymptomatic for neck pain.

How to cite this article: Natale F, Molinari R, Mollo N, Limatola M, De Luca L, Alfieri R, et al. Transient global amnesia in a patient with painless spontaneous internal carotid artery dissection: An unusual but possible underlying cause. *Curr J Neurol* 2024; 23(2): 137-9.

A 42-year-old woman was admitted to emergency room experiencing sudden memory loss. Her husband witnessed the onset of the episode. No recent head trauma was reported. At admission, patient was asymptomatic and vital parameters were normal. Anterograde and retrograde memory loss was confirmed by a neurologist and no other neurological signs were elicitable. Blood exams, toxicological analysis, and alcohol level were negative. Electrocardiography (ECG), chest X-ray, and brain computed tomography (CT) scan showed no abnormalities. At physical examination, a carotid

bruit could be appreciated.

Thus, a two-dimensional (2D) echo color-Doppler study of the carotid arteries was performed showing a left common and ICA dissection (Figure 1, a). The putative mechanism of TGA after ICA dissection is schematically shown in figure 1. Because of the dissection, the laminar flow becomes turbulent and limiting, thus resulting in reduced cerebral perfusion. The diagnosis of ICA dissection was confirmed by a contrast CT scan further excluding the coexistence of an aortic dissection. The anterograde amnesia resolved 15 hours after the admission.

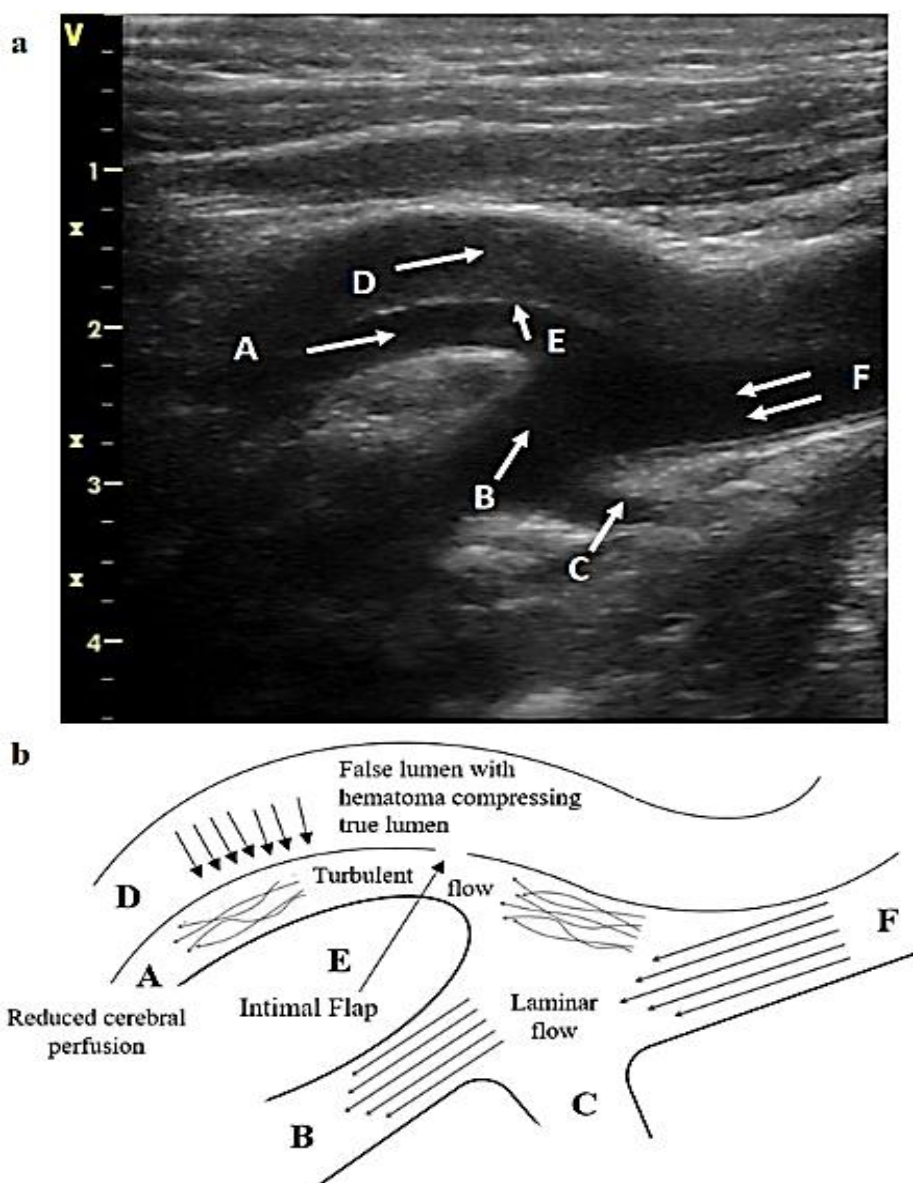


Figure 1. a) True lumen of internal carotid artery (ICA) (A), external carotid artery (B), superior thyroid artery (C), false lumen (D), intimal flap (E), common carotid artery (F); b) Schematic view of the putative mechanism of transient global amnesia (TGA) after ICA dissection

An echocardiogram without/with bubble study was also scheduled to exclude a patent foramen ovale (PFO) resulting negative. Finally, magnetic resonance imaging (MRI) with diffusion-weighted imaging was suggested to rule out ischemic stroke. It was performed 3 days later showing no abnormalities. Hence, the ICA dissection remained the only possible explanation of the patient's symptoms. The neurologist confirmed that the patient experienced an episode of TGA. After a vascular surgery consultation, a conservative treatment was deemed appropriate. At 6-month follow-up, the patient did not complain of any other neurological symptom or sign.

TGA has never been associated with a spontaneous ICA dissection to date. As reported in figure 1 (panel a and b), a sudden dissection may result in reduced cerebral perfusion because of the compression by the hematoma generated in the false lumen into the true lumen resulting in turbulent limiting flow. Accumulated evidence supports the possible role for supra-aortic trunks diseases determining ischemia as possible

underlying substrate for TGA.² In order to not miss a spontaneous ICA dissection as a rare but possible underlying condition of TGA, as for the present case, it will be helpful to perform a 2D echo color-Doppler study of the carotid arteries in patients affected by such amnesic syndrome. It is a useful and less expensive diagnostic tool with a very high predictive clinical value.⁵ It is known that TGA is a benign disorder and the treatment is mainly supportive.¹ Resolution is spontaneous, rarely recurs, and outcome is good in the majority of patients.² Risk factors management, such as losing weight, smoking discontinuation, compliance to medications, alcohol abstinence, and regular follow-up with the primary care provider is mandatory.

Conflict of Interests

The authors declare no conflict of interest in this study.

Acknowledgments

None.

References

1. Sealy D, Tiller RJ, Johnson K. Transient global amnesia. *Am Fam Physician* 2022; 105(1): 50-4.
2. Michel P, Beaud V, Eskandari A, Maeder P, Demonet JF, Eskiolou E. Ischemic amnesia: Causes and outcome. *Stroke* 2017; 48(8): 2270-3.
3. Lee BH. Transient global amnesia following carotid artery stenting: A case report. *Radiol Case Rep* 2020; 15(8): 1159-63.
4. Gaul C, Dietrich W, Tomandl B, Neundorfer B, Erbguth FJ. Aortic dissection presenting with transient global amnesia-like symptoms. *Neurology* 2004; 63(12): 2442-3.
5. Ben Hassen W, Machet A, Edjlali-Goujon M, Legrand L, Ladoux A, Mellerio C, et al. Imaging of cervical artery dissection. *Diagn Interv Imaging* 2014; 95(12): 1151-61.