



Anticoagulation in the management of septic cavernous sinus thrombosis secondary to rhino-orbito-cerebral mucormycosis: A retrospective real-world experience

Received: 10 Sep. 2023
Accepted: 08 Nov. 2023

Kiana Amani¹, Mojtaba Shahbazi², Atefeh Behkar³, Ghasem Farahmand¹, Shima Ghafouri¹, Sanaz Heydari¹, Maryam Kaeedi¹, Hana Magrouni¹, Fatemeh Alizadeh¹, Mojdeh Ghabaee², Payam Sarraf², Abbas Tafakhori², Hamed Amirifard², Sakineh Ranji-Burachaloo², Seyed Ehsan Mohammadianinejad², Melika Jameie², Mohammad Hossein Harirchian²

¹ Neurology Ward, Imam Khomeini Hospital Complex, Tehran University of Medical Sciences, Tehran, Iran

² Iranian Center of Neurological Research, Neuroscience Institute, Imam Khomeini Hospital Complex, Tehran University of Medical Sciences, Tehran, Iran

³ School of Medicine, Tehran University of Medical Sciences, Tehran, Iran

Keywords

Cavernous Sinus Thrombosis; Septic; Anticoagulants; Mucormycosis; COVID-19; Treatment Outcome

Abstract

Background: COVID-19 was associated with an increased number of patients with mucormycosis (MCR), followed by septic cavernous sinus thrombosis (SCST). We evaluated the association between anticoagulation (AC) and mortality/morbidity of COVID-19-associated MCR (CAM)-induced SCST.

Methods: In this retrospective study, neurological sequelae, functional outcomes, and in-hospital mortality were compared between AC receivers and

non-receivers. In addition, the association between AC and survivability was examined.

Results: Twenty-nine patients (17 male; mean age: 51.27 years) with CAM-induced SCST were included in the study. The median intervals between COVID-19 and MCR, and COVID-19 and SCST were 19 and 27 days, respectively.

How to cite this article: Amani K, Shahbazi M, Behkar A, Farahmand G, Ghafouri S, Heydari S, et al. Anticoagulation in the management of septic cavernous sinus thrombosis secondary to rhino-orbito-cerebral mucormycosis: A retrospective real-world experience. *Curr J Neurol* 2024; 23(1): 44-58.

Among AC recipients, the interval between SCST and AC initiation was 18 days, with an AC duration of 37 days. Baseline and management-related characteristics were comparable between AC recipients and non-recipients ($P > 0.050$). AC receivers ($n = 15$) and non-receivers ($n = 14$) did not significantly differ in terms of the proportion of sequelae (6/15 vs. 5/14; $P = 1.000$), complete recovery (2/15 vs. 4/14; $P = 0.687$), and in-hospital mortality (3/15 vs. 3/14; $P > 0.999$). Nevertheless, AC recipients had a longer hospital stay (72.0 vs. 35.5; $P = 0.016$). AC-related characteristics (AC receiving, type, early initiation, and duration) were not significantly different between survivors and non-survivors, or between recovered and disabled patients.

Conclusion: In our study, CAM-induced SCST in-hospital mortality/morbidity did not differ between AC receivers and non-receivers. AC characteristics were not different between survivors and non-survivors, or recovered and disabled patients. However, the small sample size may have limited the ability to detect significant differences, leading to inconclusive results.

Introduction

Septic cavernous sinus thrombosis (SCST) is an extremely rare condition, with an estimated mortality rate of 20 to 30% and a neurological sequelae rate of nearly 50%.¹ Despite its high mortality and morbidity, SCST treatment is mostly based on experts' opinions and some retrospective conflicting studies, owing to its rarity and the lack of randomized controlled trials (RCTs) in this regard.¹ Due to the absence of venous valves within the connections to and from the cavernous sinus structures, infections may spread to the cavernous sinuses via the ophthalmic veins or the emissary veins connected to the pterygoid venous plexus.¹ Defects in the adjacent soft tissues or bones (i.e., defects in the thin bone separating the sphenoid and cavernous sinuses) are another route for the spreading of infection to the cavernous sinuses.¹ The infection will subsequently act as a potent thrombosis stimulator, either directly by releasing prothrombotic factors or indirectly as a result of toxin-induced tissue damage.^{1,2} Important structures, including cranial nerves III, IV, V (V1 and V2 branches), and VI, internal carotid artery (ICA), and sympathetic nerve plexus pass through the cavernous sinuses, resulting in neurologic manifestations of their involvement.¹ Bacterial pathogens such as *Staphylococcus aureus* and *Streptococcus* species are the most common organisms responsible for SCST, accounting

for more than 70% of cases.^{3,4} Fungal etiologies such as *Aspergillus*, *Schizophyllum commune*, *Rhizopus* species, and *Mucor* species are less commonly reported; they are mostly observed in immunocompromised patients.^{3,5}

Mucormycosis (MCR) is caused by a group of fungi from the Mucorales scientific order, including *Rhizopus* and *Mucor* species.³ The incidence rate of MCR varies between 0.005 and 1.7 per million population globally, rising to 140 per million population in India [Mucormycosis (who.int)]. During the coronavirus disease 2019 (COVID-19) pandemic caused by the severe acute respiratory syndrome coronavirus 2 (SARS-CoV-2), which led to significant mortality and morbidity in low and middle-income countries,⁶⁻¹⁶ MCR incidence considerably increased.¹⁷⁻²¹ Steroid-mediated and SARS-CoV-2-mediated immunosuppression are assumed to be the major underlying reasons for this increase.²² COVID-19-associated MCR (CAM) affected many people in India^{21,23-25} and Iran.^{26,27} Rhino-orbito-cerebral mucormycosis (ROCM) is the most prevalent clinical presentation of CAM,^{21,28} with an overall mortality rate of 25 to 62%.²⁹ This fulminant condition affects the nasal cavity, paranasal sinuses, orbits, and intracranial structures.^{21,28} SCST can occur as a consequence of ROCM through the spreading of the infection across the orbital apex or paranasal sinuses, predominately ethmoid and/or sphenoid sinuses, to the adjacent cavernous sinuses.^{25,28,30-33} ROCM patients with brain, cavernous sinus, or carotid involvement have especially poorer prognoses.²⁹

Currently, there is no standard treatment guideline for the management of patients with SCST.¹ Although stabilization, acute resuscitation, and treatment of the underlying infection are the mainstay of treatment,^{34,35} there is no consensus regarding other treatment aspects, including the use of anticoagulation (AC).^{3,34} The majority of the evidence supporting AC for SCST treatment arises from previous case reports, and very few studies have been conducted in this regard during recent years.¹ From a theoretical point of view, AC can prevent thrombosis propagation, inhibit platelet function, exert anti-inflammatory properties, and promote antibiotic penetration into the thrombus.^{1,3,34} On the other hand, it is suggested that the thrombus might play a protective role by confining the infection and preventing septic thrombi dissemination.³⁴ Additionally, there are few reports of intracranial or systemic hemorrhagic

events after AC in patients with SCST.^{36,37}

In light of this information, we were looking for an answer to this question: Can AC reduce SCST mortality/morbidity? First, we assessed the association between AC and CAM-induced SCST mortality/morbidity. Then, we compared survivors with non-survivors, as well as patients who achieved complete recovery (modified Rankin Scale [mRS]: 0-1) with those who survived with disability (mRS: 2-5) in terms of AC-related characteristics. The importance and originality of this study are that (a) it explores an extremely rare and life-threatening condition, (b) to date, various aspects of SCST management (i.e., AC) have remained highly controversial, hence the need for real-world evidence, (c) the few available studies have mostly investigated SCST due to bacterial causes, with the majority dating back to before the year 2000, and (d) due to the rarity of SCST, it is unlikely that prospective studies with sufficient sample sizes will be conducted in the future to guide the treatment.

Materials and Methods

Study design and ethics statement: Figure 1 provides an overview of this retrospective cohort study design. The study was conducted at a tertiary referral academic hospital complex, affiliated with Tehran University of Medical Sciences, Tehran, Iran. Due to the lack of standard treatment guidelines, AC administration, as well as its type and therapy duration for each patient, was performed at the discretion of the attending neurologist and infectious disease specialist. The follow-up period started with patients' admission to the hospital with MCR symptoms and ended with their death or hospital discharge. Using a

standardized checklist, patients' medical records were objectively extracted and analyzed. The Delta variant (B.1.617.2) of COVID-19 was the dominant variant in Iran at the time of this study.³⁸ This study was approved by the local Institutional Review Board (IR.TUMS.NI.REC.1400.059) and followed the Strengthening the Reporting of Observational Studies in Epidemiology (STROBE) Statement (<https://www.equator-network.org/reporting-guidelines/strobe/>). Patients' anonymity was protected, and participants signed written informed consent forms for participation and publication according to the Declaration of Helsinki.³⁹

Due to their nature, retrospective cohort studies are prone to selection and information bias, as well as confounding factors.⁴⁰ To address the selection bias and obtain a representative sample, we consecutively included 'all' eligible patients during the study period, irrespective of the treatment group (AC receivers vs. non-receivers) or the patient's outcomes (sequelae/complications, functional outcomes, and mortality). In other words, the selection of either exposed (received AC) or non-exposed (not received AC) groups was not based on the patients' outcomes. To address the information bias, medical record retrievers and persons involved in evaluating the patients' outcomes were blinded to the research question. To reduce inaccuracies in data collection from medical records, we conducted a verification process in which data initially gathered by neurology residents was reviewed by expert attending neurologists. To address the confounding factors, various patient-related, disease-related, and management-related prognostic factors were examined for possible confounding effects, but no confounding effects were detected (Please see the "Results" section).

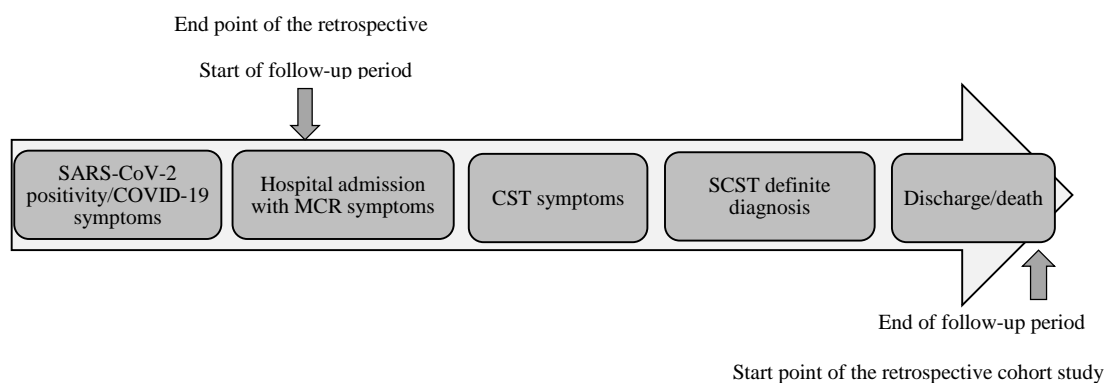


Figure 1. Study design

SARS-CoV-2: Severe acute respiratory syndrome coronavirus-2; COVID-19: Coronavirus disease-2019; MCR: Mucormycosis; CST: Cavernous sinus thrombosis; SCST: Septic cavernous sinus thrombosis

Study population: Using consecutive sampling, all patients with the following criteria were considered eligible to be included: (a) adult patients, who were (b) admitted to the hospital between March 2021 and December 2021, (c) with a confirmed diagnosis of MCR using histopathologic identification and culture of the specimen collected during endoscopic sinus biopsy,²⁹ (d) with a confirmed history of COVID-19 (positive microbiologic testing and compatible examination/imaging findings⁴¹) within 60 days prior to MCR presentation, with (e) clinically and radiologically confirmed cavernous sinus thrombosis (CST)¹ using contrast-enhanced magnetic resonance imaging (MRI) (suggested as the most sensitive imaging modality for SCST diagnosis¹). It is of note that the two-month interval between SARS-CoV-2 positivity/COVID-19 symptoms and the onset of MCR was chosen based on the intervals suggested by recent evidence (i.e., 5 to 14 days,²⁹ two to three weeks,²⁹ 20.73 ± 12.65 days,⁴² and 28 days²⁰).

The exclusion criteria were (a) patients who, despite receiving AC, did not achieve activated partial thromboplastin time (aPTT) therapeutic range, and (b) patients with non-CAM (having negative or suspected COVID-19 history).

Study measures and objectives: The primary objective of the study was to compare AC receivers and non-receivers in terms of the following features: (a) clinical/radiological neurological and extracerebral sequelae/complications (altered level of consciousness [LOC], new focal neurologic deficits [FNDs], new cerebral ischemic infarcts, new or worsening intracranial hemorrhage [ICH], new intracranial abscess, as well as extracerebral thrombotic or hemorrhagic events), (b) length of hospital stay, (c) functional outcomes at discharge according to the mRS score,⁴³ and (d) CAM-induced SCST in-hospital mortality. To further evaluate our research question, our secondary objectives were to find out whether survivors and non-survivors, as well as individuals who completely recovered (mRS: 0-1) and those who survived with disability (mRS: 2-5) differ in terms of AC-related characteristics (AC receiving, type, early initiation, and in-hospital therapy duration).

Medical records were retrospectively reviewed by neurology residents for the following information: (a) age and sex, (b) MCR predisposing factors (diabetes mellitus [DM], receiving glucocorticoids [GC] for COVID-19 treatment, underlying malignancy, and other

immunocompromised conditions²⁹), (c) presenting manifestations (visual impairment, FNDs attributed to the local compression of cranial nerves [ophthalmoplegia due to III, IV, and VI cranial neuropathy, as well as numbness, pain, or paresthesia in trigeminal territory due to V1 and V2 branches neuropathy], altered LOC, and other FNDs [aphasia, motor deficit, and sensory deficit]), (d) additional initial neuroradiologic findings in brain MRI/computed tomography (CT) other than CST (cerebral ischemic infarcts, ICH, and intracranial abscess), (e) critical intervals (intervals between the onset of COVID-19 symptoms and MCR onset, COVID-19 symptoms and SCST presentation, SCST presentation and its definite diagnosis, SCST presentation and receiving AC, and MCR presentation and debridement surgery), (f) AC-related characteristics (AC type [unfractionated heparin (UFH), low molecular weight heparin (LMWH), or direct oral anticoagulants (DOACs)], interval between SCST presentation and AC initiation, and in-hospital AC therapy duration), (g) other management-related characteristics (antifungal therapy, anticonvulsant therapy, and debridement surgery), and (h) patients' outcomes (sequelae/complications, length of hospital stay, functional outcomes at discharge, and in-hospital mortality).

Complete recovery, surviving with disability, and death were defined as mRS scores 0-1, 2-5, and 6, respectively.⁴³ Early AC initiation was defined as initiating AC within 7 days of CST manifestation.⁴⁴ Radiological neurological sequelae were assessed using brain MRI or CT.

All statistical analyses were conducted using SPSS software (Version 26, IBM Corp., Armonk, NY, USA). The normality of variables was assessed using the Shapiro-Wilk test and quantile-quantile plot. Categorical data were presented as frequency (percentage). Symmetric numeric data were summarized using mean \pm standard deviation (SD). Asymmetric data were described by median [interquartile range (IQR)]. The relation between group and categorical variables was evaluated using Fisher's exact test. The independent t-test and exact Mann-Whitney U test were used to compare the distribution of numeric variables between groups. P-values of less than 0.05 were considered statistically significant. No data were missing, and there was no loss to follow-up.

Results

Frequency of cavernous sinus thrombosis in

patients with rhino-orbito-cerebral MCR: Figure 2 illustrates the flow diagram of participants. Among 244 patients with confirmed MCR, 32 patients had clinical and radiological evidence of CST, 3 of whom were excluded for the following reasons: not achieving aPTT therapeutic range, despite receiving AC (n = 2), and negative history of COVID-19 (n = 1). Therefore, a total of 29 patients with CAM-induced SCST were included in the study.

We found a CST frequency of 13.1% among 244 patients with ROCM (32/244).

Patients' demographic and baseline clinico-radiological characteristics

Individual demographic, clinico-radiological, AC-related, and outcome-related characteristics of all patients are presented in detail in table 1.

Total cohort: Table 2 provides the cohort characteristics and compares these characteristics according to the patients' AC status. Seventeen patients (58.6%) were men, and the mean age at diagnosis was 51.27 ± 11.41 years (age range: 20-72 years). According to the National Institute of Health (NIH) guideline pertaining to COVID-19 severity categories,⁴⁵ all patients exhibited severe to critical manifestations of underlying COVID-19 infection. The median interval between COVID-19

symptoms and MCR onset was 19 days [IQR: 11.0, 25.0] (range: 4-56 days), and the median interval between COVID-19 symptoms and SCST manifestations was 27 days [IQR: 18.5, 36.0] (range: 6-180 days). There was a median of 7 days [3.5, 30.0] between SCST initial manifestations and its definite diagnosis. MCR predisposing factors included DM (75.9%), receiving GC for COVID-19 treatment (58.6%), other immunocompromised conditions such as end-stage renal disease (ESRD) and inflammatory bowel disease (IBD) (6.9%), and underlying malignancy (3.4%). Patients mostly manifested with trigeminal neuropathy/ophthalmoplegia (89.7%) and visual impairment (75.9%). Cerebral ischemic infarction (20.7%) and intracranial abscess (13.8%) were the most common initial neuroradiologic findings in brain MRI/CT (other than CST). Baseline demographic and clinico-radiological features were balanced between the treatment groups, and no possible confounding effects were detected.

Anticoagulated patients: Fifteen out of 29 patients (51.7%) were anticoagulated (mean age: 49.80 ± 10.30 years, male: 8/15). The median duration between COVID-19 infection and the onset of MCR and SCST manifestations was 18 [11.0, 30.0] days and 30 [17.0, 53.0] days, respectively.

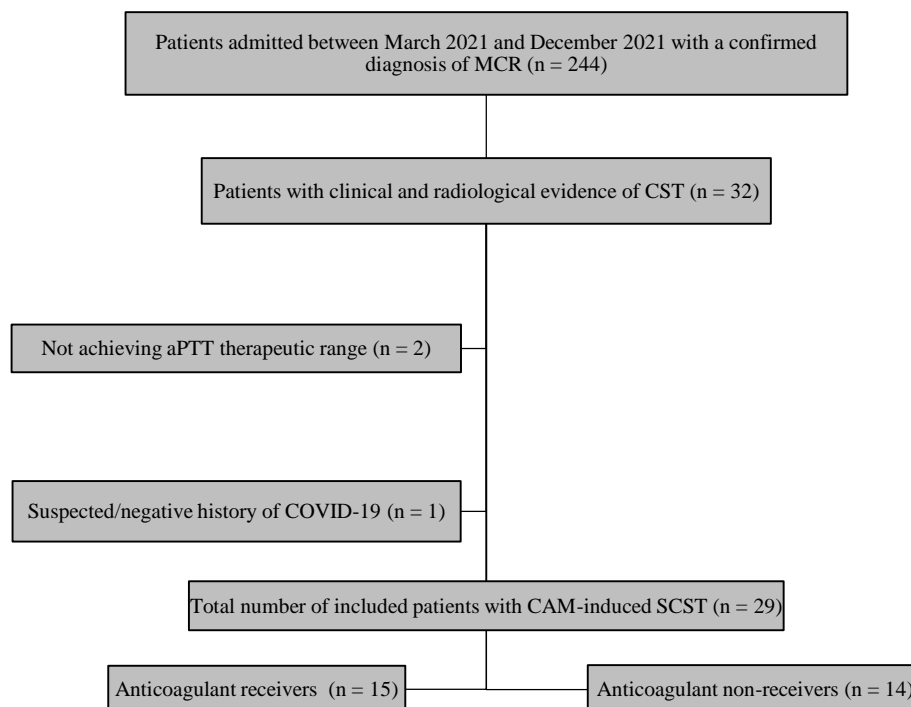


Figure 2. The flow diagram of participants

MCR: Mucormycosis; CST: Cavernous sinus thrombosis; aPTT: Activated partial thromboplastin time; COVID-19: Coronavirus disease-2019; CAM: COVID-19 associated mucormycosis; SCST: Septic cavernous sinus thrombosis

Table 1. Characteristics of 29 patients with COVID-19-associated-mucormycosis-induced septic cavernous sinus thrombosis (SCST)

Demographic and clinico-radiological characteristics				AC-related characteristics			Sequelae/complications and outcomes			
Sex	Age (year)	Predisposing factors	Presenting manifestations	Radiologic findings [†]	AC	Early initiation	Duration*	Clinical sequelae/complication	Radiological sequelae/complication [‡]	Outcome
F	51	COVID-19, Receiving GC, DM	Visual impairment, Trigeminal neuropathy/ ophthalmoplegia, Other FNDs [§] /altered LOC	NL	DOACs	No	22	No new sequelae	No new sequelae	Discharged (mRS = 3)
F	28	COVID-19, DM	Visual impairment, Trigeminal neuropathy/ophthalmoplegia	NL	DOACs	No	104	No new sequelae	No new sequelae	Discharged (mRS = 2)
F	45	COVID-19, Receiving GC, DM	Visual impairment, Trigeminal neuropathy/ophthalmoplegia, Other FNDs/altered LOC	Ischemic infarcts	DOACs	Yes	60	Extracranial left ICA thrombosis, PTE	New ischemic infarcts	Discharged (mRS = 2)
M	51	COVID-19	Visual impairment, Trigeminal neuropathy/ophthalmoplegia	NL	DOACs	Yes	81	No new sequelae	No new sequelae	Discharged (mRS = 2)
M	34	COVID-19	Visual impairment, Trigeminal neuropathy/ophthalmoplegia	Abscess	LMWH	No	40	No new sequelae	No new sequelae	Discharged (mRS = 2)
M	47	COVID-19, Other IC conditions	Visual impairment, Trigeminal neuropathy/ophthalmoplegia, Other FNDs/altered LOC	Ischemic infarcts, Abscess	LMWH	Yes	55	New FND	New ICH	Discharged (mRS = 2)
F	56	COVID-19, Receiving GC	Trigeminal neuropathy/ophthalmoplegia	NL	UFH	No	37	No new sequelae	No new sequelae	Discharged (mRS = 2)
M	46	COVID-19, Receiving GC, DM	Visual impairment, Trigeminal neuropathy/ophthalmoplegia	NL	UFH	No	38	No new sequelae	No new sequelae	Discharged (mRS = 3)
M	60	COVID-19, DM, Underlying malignancy	Visual impairment, Trigeminal neuropathy/ophthalmoplegia, Other FNDs/altered LOC	NL	UFH	Yes	25	altered LOC	No new sequelae	Death
M	50	COVID-19, DM	Visual impairment, Trigeminal neuropathy/ophthalmoplegia	Abscess	UFH	No	18	No new sequelae	No new sequelae	Discharged (mRS = 3)
M	66	COVID-19, Receiving GC, DM	Visual impairment	NL	UFH	No	14	No new sequelae	No new sequelae	Discharged (mRS = 1)
F	48	COVID-19, DM	Visual impairment, Trigeminal neuropathy/ophthalmoplegia, Other FNDs/altered LOC	Ischemic infarcts	UFH	Yes	22	altered LOC	No new sequelae	Death
F	56	COVID-19, Receiving GC, DM	Visual impairment, Trigeminal neuropathy/ophthalmoplegia	NL	UFH	Yes	37	altered LOC, New FND	New ischemic infarcts	Death
F	65	COVID-19, Receiving GC, DM	Trigeminal neuropathy/ophthalmoplegia	NL	UFH	Yes	29	Extracranial left ICA thrombosis	No new sequelae	Discharged (mRS = 1)
M	44	COVID-19, DM	Visual impairment, Trigeminal neuropathy/ophthalmoplegia	NL	UFH	No	47	No new sequelae	New ischemic infarcts	Discharged (mRS = 2)
M	47	COVID-19, Receiving GC, DM	Visual impairment	NL	None	N/A	N/A	No new sequelae	No new sequelae	Discharged (mRS = 2)

Table 1. Characteristics of 29 patients with COVID-19-associated-mucormycosis-induced septic cavernous sinus thrombosis (SCST) (continue)

Demographic and clinico-radiological characteristics				AC-related characteristics			Sequelae/complications and outcomes			
Sex	Age (year)	Predisposing factors	Presenting manifestations	Radiologic findings [†]	AC	Early initiation	Duration*	Clinical sequelae/complication	Radiological sequelae/complication [‡]	Outcome
F	55	COVID-19, Receiving GC, DM	Visual impairment, Trigeminal neuropathy/ophthalmoplegia	NL	None	N/A	N/A	No new sequelae	No new sequelae	Discharged (mRS = 3)
M	72	COVID-19, Receiving GC, DM	Visual impairment, Trigeminal neuropathy/ophthalmoplegia	NL	None	N/A	N/A	New FND	New ischemic infarcts	Discharged (mRS = 5)
F	54	COVID-19, DM	Trigeminal neuropathy/ophthalmoplegia	Ischemic infarcts	None	N/A	N/A	altered LOC	No new sequelae	Death
M	20	COVID-19, DM	Visual impairment, Trigeminal neuropathy/ophthalmoplegia	Ischemic infarcts, ICH, Abscess	None	N/A	N/A	No new sequelae	No new sequelae	Discharged (mRS = 2)
M	50	COVID-19, Receiving GC, DM	Visual impairment, Trigeminal neuropathy/ophthalmoplegia, Other FNDs/altered LOC	Ischemic infarcts	None	N/A	N/A	altered LOC, New FND	New intracranial abscess	Death
M	65	COVID-19, Receiving GC, DM	Visual impairment, Trigeminal neuropathy/ophthalmoplegia	NL	None	N/A	N/A	No new sequelae	No new sequelae	Discharged (mRS = 1)
F	62	COVID-19, Receiving GC, DM	Trigeminal neuropathy/ophthalmoplegia	NL	None	N/A	N/A	No new sequelae	No new sequelae	Discharged (mRS = 0)
F	64	COVID-19, Receiving GC, DM	Trigeminal neuropathy/ophthalmoplegia	NL	None	N/A	N/A	altered LOC, New FND	Not performed**	Death
M	60	COVID-19, Receiving GC, DM	Visual impairment, Trigeminal neuropathy/ophthalmoplegia	NL	None	N/A	N/A	No new sequelae	No new sequelae	Discharged (mRS = 2)
M	38	COVID-19	Trigeminal neuropathy/ophthalmoplegia	NL	None	N/A	N/A	No new sequelae	No new sequelae	Discharged (mRS = 1)
M	52	COVID-19, DM	Visual impairment, Trigeminal neuropathy/ophthalmoplegia	NL	None	N/A	N/A	altered LOC, oral mucosal bleeding	No new sequelae	Discharged (mRS = 2)
M	43	COVID-19, Receiving GC	Visual impairment, Trigeminal neuropathy/ophthalmoplegia	NL	None	N/A	N/A	No new sequelae	No new sequelae	Discharged (mRS = 3)
F	55	COVID-19, Receiving GC, Other IC conditions	Other FNDs	NL	None	N/A	N/A	No new sequelae	No new sequelae	Discharged (mRS = 0)

CAM: COVID-19 associated mucormycosis; COVID-19: Coronavirus disease 2019; SCST: Septic cavernous sinus thrombosis; F: Female; M: Male; AC: Anticoagulation; GC: Glucocorticoids; DM: Diabetes mellitus; IC: Immunocompromised; mRS: Modified rankin scale; LOC: Level of consciousness; ICH: Intracranial hemorrhage; FND: Focal neurologic deficit; UFH: Unfractionated heparin; LMWH: Low molecular weight heparin; DOACs: Direct oral anticoagulants; ICA: Internal carotid artery; PTE: Pulmonary thromboembolism; N/A: Not applicable

[†]Initial neuroradiologic findings in brain MRI/CT other than CST, [‡]Radiological sequelae assessment using brain neuroimaging (MRI or CT), [§]Other FNDs: FNDs other than trigeminal neuropathy/ophthalmoplegia, *In-hospital therapy duration, **Did not perform due to the patient's unstable condition, following altered LOC and new FND.

Table 2. Patients' demographic, clinico-radiological, and management-related characteristics according to anticoagulation (AC) status

Characteristics	All (n = 29)	AC receivers (n = 15)	AC non-receivers (n = 14)	P [†]
Baseline characteristics				
Sex (male)	17 (58.6)	8 (53.3)	9 (64.3)	0.710
Age (years)	51.27 ± 11.41	49.80 ± 10.30	52.64 ± 13.08	0.519
COVID-19 onset to MCR onset (days)	19.0 [11.0, 25.0]	18.0 [11.0, 30.0]	19.0 [13.0, 24.0]	0.878
COVID-19 onset to SCST onset (days)	27.0 [18.5, 36.0]	30.0 [17.0, 53.0]	26.5 [19.8, 34.0]	0.810
SCST onset to SCST diagnosis (days)	7.0 [3.5, 30.0]	17.0 [2.0, 31.0]	7.0 [3.8, 32.0]	0.983
MCR predisposing factors				
DM	22 (75.9)	11 (73.3)	11 (78.6)	> 0.999
Receiving GC as COVID-19 treatment	17 (58.6)	7 (46.7)	10 (71.4)	0.264
Underlying malignancy	1 (3.4)	1 (6.7)	0 (0)	1.000
Other immunocompromised conditions	2 (6.9)	1 (6.7)	1 (7.1)	> 0.999
Presenting manifestations				
Visual impairment	22 (75.9)	13 (86.7)	9 (64.3)	0.215
Trigeminal neuropathy/ophthalmoplegia	26 (89.7)	14 (93.3)	12 (85.7)	0.598
Aphasia/ motor deficit/sensory deficit/ altered LOC	6 (20.7)	5 (33.3)	1 (7.1)	0.169
Initial neuroradiologic findings in brain MRI/CT other than CST				
Cerebral ischemic infarcts	6 (20.7)	3 (20.0)	3 (21.4)	> 0.999
ICH	1 (3.4)	0 (0)	1 (7.1)	0.483
Intracranial abscess	4 (13.8)	3 (20.0)	1 (7.1)	0.598
AC-related characteristics (n = 15)				
SCST onset to AC initiation (days)	N/A	18.0 [7.0, 42.0]	N/A	N/A
Early AC initiation (yes)	N/A	7 (46.7)	N/A	N/A
AC therapy duration (days) [‡]	N/A	37.0 [22.0, 55.0]	N/A	N/A
Other management-related characteristics				
Antifungal therapy duration (days) [‡]	49.0 [27.5, 83.0]	66.0 [39.0, 92.0]	35.0 [14.5, 70.8]	0.055
Debridement surgery	28 (96.6)	15 (100)	13 (92.9)	> 0.999
MCR onset to debridement surgery (days)	14.0 [5.0, 27.0]	16.0 [5.0, 27.0]	9.0 [4.0, 31.0]	0.489
Anticonvulsant therapy	5 (17.2)	2 (13.3)	3 (21.4)	0.651

Categorical data are presented as numbers (%). Symmetric numeric data are summarized by mean ± standard deviation (SD) and asymmetric numeric data are described using median [IQR].

IQR: Interquartile range; P: Probability value; AC: Anticoagulant; COVID-19: Coronavirus disease-2019; MCR: Mucormycosis; SCST: Septic cavernous sinus thrombosis; GC: Glucocorticoids; LOC: Level of consciousness; MRI: Magnetic resonance imaging; CT: Computed tomography; ICH: Intracranial hemorrhage; N/A: Not applicable; DM: Diabetes mellitus

[†]P-value of the comparison between AC receivers and non-receivers, [‡]In-hospital therapy duration

There was a 17-day delay [2.0, 31.0] between the onset of SCST and its definite diagnosis in this subgroup of patients. DM and a history of receiving GC were present in 11/15 and 7/15 patients, respectively. Trigeminal neuropathy/ophthalmoplegia (14/15) and visual impairment (13/15) were the most common manifestations. Initial neuroimaging evaluations revealed cerebral ischemic infarcts and intracranial abscesses in 3/15 and 3/15 patients, respectively.

Non-anticoagulated patients: Fourteen out of 29 patients (48.3%) did not receive AC treatment (mean age: 52.64 ± 13.08 years, male: 9/14). The median duration from COVID-19 infection to MCR and SCST manifestations was 19.0 [13.0, 24.0] and 26.5 [19.8, 34.0] days, respectively. In this subgroup of patients, there was a delay of 7.0 [3.8, 32.0] days between the onset of SCST symptoms and the definitive diagnosis. Among these patients, 11/14 had DM, and 10/14 had a history of receiving GC. The most common manifestations were trigeminal neuropathy/ophthalmoplegia in 12/14 patients and visual impairment in 9/14 patients. Initial neuroimaging assessments revealed cerebral ischemic infarcts in 3/14 patients, ICH in 1/14, and intracranial abscesses in 1/14 patients.

Patients' management-related characteristics

Total cohort: All patients received antifungal therapy, with a median in-hospital therapy duration of 49 days [27.5, 83.0]. All patients except one underwent debridement surgery, with a median interval of 14 [5.0, 27.0] days following the onset of MCR symptoms. The unstable condition of one patient (patient 24) did not permit surgery, and she passed away 14 days after admission (Table 1). Moreover, 5 (17.2%) patients received anticonvulsant therapy. Except for AC status, there was no significant difference in management approaches between AC receivers and non-receivers, indicating no possible confounding effects (Table 2).

Anticoagulated patients: Individual AC-related characteristics are presented in table 1. Of the 15 anticoagulated patients, 9, 4, and 2 received UFH, DOACs, and LMWH, respectively. The median interval between SCST symptoms and AC initiation was 18 days [IQR: 7.0, 42.0], and 7/15 AC-receivers were anticoagulated within a week from SCST onset. The median in-hospital AC therapy duration was 37 days [IQR: 22.0, 55.0] (Table 2). All AC receivers received antifungals with a median duration of 66.0 [39.0, 92.0] days. Additionally, all underwent debridement surgery

within a median of 16.0 [5.0, 27.0] days of MCR manifestations. Anticonvulsant therapy was administered in 2/15 patients.

Non-anticoagulated patients: All patients received antifungal medication for a median duration of 35.0 [14.5, 70.8] days. Furthermore, except for one individual, all patients underwent debridement surgery within a median timeframe of 9.0 [4.0, 31.0] days after the appearance of MCR symptoms. Anticonvulsant therapy was given to 3/14 patients.

Patients' outcomes

Total cohort: Table 3 indicates the total cohort outcomes and compares patients' outcomes according to their AC status. Sequelae/complications occurred in 37.9% of patients, with altered LOC (24.1%) and new FNDs (17.2%) being the most frequent clinical sequelae, and new cerebral ischemic infarction (13.8%) being the most frequent neuroradiological sequelae. The overall median length of hospitalization was 54 days [29.0, 77.5]. Most of the patients (58.6%) survived with disability, and 20.7% achieved complete recovery at hospital discharge. The overall in-hospital mortality rate was 20.7%. AC receivers and non-receivers did not significantly differ in terms of clinical and neuroradiological sequelae/complications ($P > 0.999$). The median length of hospitalization was significantly longer in AC receivers ($P = 0.016$). No significant differences were observed between AC receivers and non-receivers in terms of in-hospital mortality rate ($P > 0.999$), and functional outcomes at discharge ($P = 0.687$).

Anticoagulated patients: Sequelae/complications were observed in 6 of the 15 AC receivers. Among AC receivers, none had extracerebral hemorrhagic events, while 1 case, who had received LMWH, presented a new ICH and was discharged with a slight disability (mRS = 2) (Table 1; patient 6). The median length of hospitalization was 72.0 [46.0, 95.0] days. Complete recovery was achieved in 2/15 patients and 10/15 were discharged with disabilities. Additionally, 3 out of 15 AC receivers were deceased.

Non-anticoagulated patients: Sequelae/complications occurred in 5 of 14 AC non-receivers. Among the AC non-receivers, one patient had an extracerebral hemorrhagic event (Table 1; patient 27 with oral mucosal bleeding), and none had extracerebral thrombotic events. The median length of hospitalization was 35.5 [16.3, 56.8] days.

Table 3. Patients' outcomes according to anticoagulation (AC) status

Outcome	All (n = 29)	AC receivers (n = 15)	AC non-receivers (n = 14)	P [†]
Clinical and neuroradiological** sequelae/complications				
Any	11 (37.9)	6 (40.0)	5 (35.7)	> 0.999
Altered LOC	7 (24.1)	3 (20.0)	4 (28.6)	0.682
New FND	5 (17.2)	2 (13.3)	3 (21.4)	0.651
New cerebral ischemic infarcts**	4 (13.8)	3 (20.0)	1 (7.1)	0.598
New intracranial abscess**	1 (3.4)	0 (0)	1 (7.1)	0.483
New or worsening ICH**	1 (3.4)	1 (6.7)	0 (0)	> 0.999
Extracerebral hemorrhagic events	1 (3.4)	0 (0)	1 (7.1)	0.400
Extracerebral thrombotic events	2 (6.9)	2 (13.3)	0 (0)	0.483
Length of hospitalization and functional outcomes at discharge				
Hospital stay (days)	54.0 [29.0, 77.5]	72.0 [46.0, 95.0]	35.5 [16.3, 56.8]	0.016*
Total cohort mRS (n = 29)				0.687
Complete recovery (mRS: 0-1)	6 (20.7)	2 (13.3)	4 (28.6)	
Disability (mRS: 2-5)	17 (58.6)	10 (66.7)	7 (50.0)	
Death (mRS: 6)	6 (20.7)	3 (20.0)	3 (21.4)	
Survivors' mRS [‡] (n = 23)				0.371
Complete recovery (mRS: 0-1)	6 (26.1)	2 (16.7)	4 (36.4)	
Disability (mRS: 2-5)	17 (73.9)	10 (83.3)	7 (63.6)	
CAM-induced SCST-related mortality				
In-hospital mortality	6 (20.7)	3 (20.0)	3 (21.4)	> 0.999

Categorical data are presented as numbers (%). Asymmetric numeric data are described using median [IQR].

IQR: Interquartile range; P: Probability value; AC: Anticoagulation; LOC: Level of consciousness; FND: Focal neurologic deficit; ICH: Intracranial hemorrhage; mRS: Modified Rankin scale; CAM: COVID-19 associated mucormycosis; COVID-19: Coronavirus disease-2019; SCST: Septic cavernous sinus thrombosis

[†]P-value of the comparison between AC receivers and non-receivers, [‡]This variable is only defined for survivors (n = 23),

*Significant at P-value < 0.05, **Radiological sequelae assessment using brain neuroimaging (MRI or CT)

Complete recovery was achieved in 4/14 patients, and 7/14 were discharged with disabilities. Additionally, 3 out of 14 AC non-receivers were deceased.

Patients' AC-related characteristics according to functional outcomes and mortality status

As shown in table 4, no significant difference was found between the survivors and non-survivors in terms of receiving AC (12 of 23 survivors vs. 3 of 6 non-survivors; $P > 0.999$), AC type ($P = 0.684$), in-hospital AC therapy duration (39.0 vs. 25.0 days; $P = 0.247$), and the proportion of patients with early AC initiation (4 of 12 AC receivers who survived vs. 3 of 3 AC receivers who did not survive; $P = 0.077$).

Similarly, the comparison between patients with complete recovery and those surviving with disability yielded no significant difference in terms of AC-related characteristics, including receiving AC (2 of 6 recovered patients vs. 10 of 17 disabled patients; $P = 0.371$), AC type ($P = 0.636$), early AC initiation proportion (1 of 2 AC receivers who recovered vs. 3 of 10 AC receivers who were disabled; $P > 0.999$), and in-hospital AC therapy duration (21.5 vs. 43.5 days; $P = 0.086$).

Discussion

Figure 3 illustrates a summary of the present research. In this study, we found no significant relation between AC and MCR-induced SCST mortality and morbidity (clinical and neuroradiological sequelae/complications, as well as functional outcomes at discharge). Furthermore, we observed no significant differences between survivors vs. non-survivors and recovered vs. disabled patients in terms of receiving AC, AC type, early AC initiation, and in-hospital AC therapy duration. Among AC receivers, a new ICH was developed in one patient, and no systemic hemorrhage was observed. Hereafter, we discuss our findings within the context of literature related to CAM, MCR-induced SCST, and controversial issues surrounding AC in SCST, respectively.

COVID-19 associated MCR: Consistent with previous studies, we observed male and middle-aged predominancies in patients with CAM.^{21,25} We found a median interval of 19 days between the COVID-19 onset and MCR symptoms, which was in agreement with previous studies, suggesting intervals varied between 5 to 21 days between admission for COVID-19 and MCR symptoms onset.^{19,20,24,25,42}

Table 4. Patients' anticoagulation-related characteristics according to functional outcomes and mortality status

Variable	Mortality (n = 29)		P	Functional outcomes [†] (n = 23)		P
	Survivors (n = 23)	Non-survivors (n = 6)		Recovered (n = 6)	Disabled (n = 17)	
Receiving AC	12 (52.2)	3 (50.0)	> 0.999	2 (33.3)	10 (58.8)	0.371
AC Type	UFH: 6 (50.0) LMWH: 2 (16.7) DOACs: 4 (33.3)	UFH: 3 (100) LMWH: 0 DOACs: 0	0.684	UFH: 2 (100) LMWH: 0 DOACs: 0	UFH: 4 (40.0) LMWH: 2 (20.0) DOACs: 4(40.0)	0.636
Early AC initiation	4 (33.3)	3 (100)	0.077	1 (50)	3 (30)	> 0.999
AC duration (days) [‡]	39.0 [23.8, 58.8]	25.0 [22.0, §]	0.247	21.5 [14.0, §]	43.5 [33.3, 65.3]	0.086

Categorical data are presented as numbers (%). Asymmetric numeric data are described using median [IQR].

IQR: Interquartile range; P: Probability value; AC: Anticoagulation; UFH: Unfractionated heparin; LMWH: Low molecular weight heparin; DOACs: Direct oral anticoagulants

[†]This variable is only defined for survivors (n = 23), recovered (mRS: 0-1), and disabled (mRS: 2-5). [‡]In-hospital therapy duration, [§]IQR is not available due to the sample size

Joshi et al. reported a longer median interval of 28 days.²⁰ In corroboration with previous studies, our findings indicated DM and GC intake as the most common CAM predisposing factors.^{20,21,24,25} At the initial neuroradiologic examination, cerebral ischemic infarcts were observed in nearly one-fifth of our patients. Similarly, there are reports of large vessels and lacunar cerebral infarcts in patients with CAM.^{31,32}

MCR-induced SCST: Before the COVID-19 pandemic, studies dealing with SCST secondary to MCR were mainly based on case reports.⁴⁶⁻⁴⁸ During the pandemic, a sudden increase was observed in MCR infections,^{28,49} resulting in a considerable increase in its cerebrovascular complications, such as the SCST.^{31,32} A retrospective

study in a large Indian tertiary hospital reported only 25 cases of SCST with fungal etiologies during a 15-year period (2002-2017).⁴ However, in the present study, we reported 29 patients with MCR-induced SCST in less than a year.

Reviewing the literature indicates few studies focusing on CAM-induced SCST.^{21,24,28,32} Recent single-center and multicenter series suggested that cavernous sinus thrombosis/invasion is among the most predominant CNS involvements in patients with ROCM.^{21,25,50} Nevertheless, there are inconsistencies in the reported frequencies of CST secondary to COVID-19-associated ROCM; 7.0%,²⁰ 10.08%,²⁵ 18.36%,²¹ and 28.0%⁵⁰ have been reported. The corresponding value in our study was 13.1% among patients with ROCM.

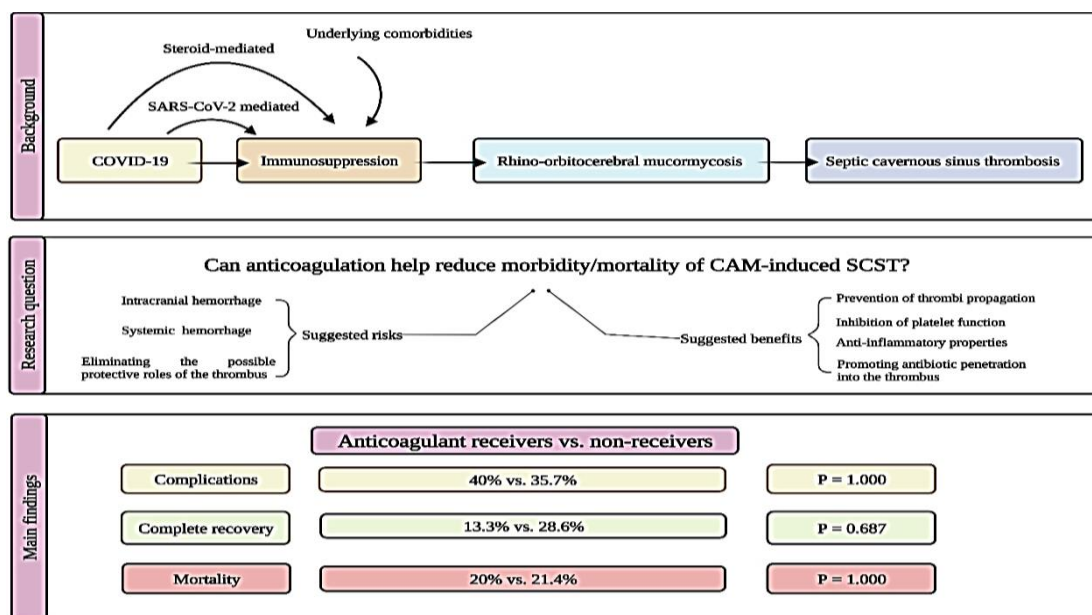


Figure 3. Research summary

SARS-CoV-2: Severe acute respiratory syndrome coronavirus-2; COVID-19: Coronavirus disease-2019; CAM: COVID-19 associated mucormycosis; SCST: Septic cavernous sinus thrombosis

In line with the current estimated SCST mortality rate of 20-30%,¹ we found an in-hospital mortality rate of 20.7% in patients with CAM-induced SCST. A lower mortality rate of 8.3% (1/12) in patients with non-CAM-induced SCST was reported by van der Poel et al.⁵¹

AC in SCST: The focus of our study was to assess the AC effects in the management of patients with CAM-induced SCST. A PubMed search, using the search query "(Cavernous Sinus Thrombosis [MeSH Terms]) AND (Anticoagulants [MeSH Terms])" revealed that the majority of the available evidence comes from older studies,^{5,36,44} and very few studies have recently dealt with AC safety/efficacy in patients with SCST.⁵¹ Additionally, those few studies had mainly investigated SCST due to bacterial causes, and the management of patients with fungal causes has scarcely been investigated.⁵¹

Currently, there is no consensus nor are there any RCTs for guiding SCST treatment,¹ hence the necessity of reporting real-world observations of this life-threatening condition. In the absence of RCTs and the relatively small sample sizes of the retrospective studies, Caranfa and Yoon suggested that extrapolating knowledge from cerebral venous sinus thrombosis (CVST) may appear reasonable.¹ Studies have suggested the acceptable safety and efficacy of AC in CVST.^{1,52} Nevertheless, we found no significant differences between AC receivers and non-receivers in terms of sequelae/complications (40.0% vs. 35.7%), in-hospital complete recovery rates (13.3% vs. 28.6%), and in-hospital mortality rates (20.0% vs. 21.4%). Nevertheless, it is important to remember that when the sample size is small, there is reduced statistical power to identify true differences between groups; thus, caution must be taken in interpreting the findings. Compared to AC non-receivers, AC receivers had longer hospitalization, possibly due to the longer time required for the adjustment of AC dose and regimen. We also observed that survivors and non-survivors, as well as completely recovered patients and those surviving with disability did not significantly differ in terms of AC-related characteristics, suggesting that AC, even when started early, did not significantly affect SCST-related mortality and morbidity. Nevertheless, some previous studies by Southwick et al.,³⁶ Levine et al.,⁴⁴ and Weerasinghe and Lueck⁵ suggested that if started early, AC might be associated with lower mortality, morbidity, or both.

Southwick et al. reviewed 86 patients with

SCST between 1940-1984, 32% of which had received heparin.³⁶ According to the authors, mortality was lower among patients who received heparin in comparison to those who did not (14% vs. 36%; $P < 0.05$). They suggested that AC must be considered as an adjuvant therapy only if there is no evidence of cortical venous infarction.³⁶ In contrast, Levine et al. studied seven patients with SCST and cases reported between 1941 and 1988, and found no significant difference in mortality rates between AC receivers and non-receivers.⁴⁴ However, they reported that early AC was associated with reduced morbidity (vision loss, stroke, ophthalmoplegia, hypopituitarism, and focal seizures), while delayed use provided no further benefit.⁴⁴ Reviewing 88 patients with SCST reported between 1980-2015, Weerasinghe and Lueck found a considerably greater percentage of full recovery (53.6% vs. 32.0%) and lower mortality (12% vs. 28%) in patients treated with AC.⁵ However, they reported no considerable difference in the number of patients surviving with disability between the two groups (34% vs. 40%).⁵ Wang et al. conducted a review of seven patients with CST secondary to sphenoid sinusitis, reported between 2001 and 2013, and included a new patient observed in their department.⁵³ They reported that compared to AC non-receivers, patients who had received intravenous/oral AC (6 of 8 patients) had a better prognosis, without ICH occurrence.⁵³ Reporting 12 patients with SCST between 2005 and 2017, of whom 7 were anticoagulated, van der Poel et al. suggested the safety of AC in these patients.⁵¹ According to the authors, none of the patients treated with AC developed hemorrhagic complications.⁵¹ However, this study did not compare the efficacy outcomes between AC receivers and non-receivers.⁵¹ Rebelo et al. reviewed 11 pediatric patients with thrombotic complications of head and neck infections between 2009 and 2013, all of whom were anticoagulated with LMWH.⁵⁴ Patients developed extracranial and intracranial thrombi, including thrombus of the transverse ($n = 3$), sagittal ($n = 1$), sigmoid ($n = 6$), and cavernous ($n = 2$) sinuses.⁵⁴ Within a median of 3.4 months, thrombus improvement or resolution occurred in 10/11 patients, with no AC-related adverse events (AEs).⁵⁴ Although remaining controversial, the authors suggested that AC benefits might outweigh the risks.⁵⁴

AC type and duration in SCST: Attempts to find the AC of choice and the optimal therapy duration have also yielded inconsistent results.¹ Continuous

heparin infusion is generally the recommended AC therapy, based on limited data.³ Accordingly, UFH was administered to the majority of our patients. Consistently, Bhatia and Jones suggested the use of UFH in the early phases of the treatment, as it is more easily reversed.³⁴ There are very few reports of LMWH being administered in patients with SCST.^{3,54} Rebelo et al. reported no AC-related AEs in 11 patients with thrombotic complications of head and neck infections who were treated with LMWH, including 2 patients with CST.⁵⁴ However, there are also anecdotal reports of hemorrhagic sequelae in patients with septic lateral sinus thrombosis on LMWH.^{55,56} In our study, two patients were treated with LMWH, one of whom developed a new ICH.

The optimal AC therapy duration of 3-6 months was recommended by van der Poel et al.,⁵¹ while some other experts believe that radiologic evidence of thrombus resolution is the treatment goal, which might be achieved within 6 weeks.³⁴ Southwick recommend continuing AC until observing significant improvement in infection and SCST clinical signs/symptoms (periorbital edema, fever, leukocytosis, etc.).³

Limitations: This study was faced with several potential limitations. First, as with previous studies, the potential limitation of a small sample size might have lowered the power of statistical test results, the possibility of performing multivariate tests, and the study's generalizability. Therefore, the outcome analyses should be interpreted with caution, and no definite scientific conclusions should be made. Indeed, the small sample size may limit the ability to detect significant differences between AC receivers and non-receivers, leading to inconclusive results. Second, we did not randomize the assignment of patients to receive AC or not, which could introduce confounding variables and affect the validity of the results. The decision to administer AC may have been influenced by various factors, including the severity of the condition, the presence of comorbidities, and individual physician preferences. However, the evaluation of various patient-related, disease-related, and management-related factors did not reveal any confounding effects. Third, certain potential confounding factors were not taken into account, such as the extent of MCR involvement or specific details regarding the concurrent use of other therapeutic interventions alongside AC. Fourth, this study exclusively encompassed patients from

a specific group diagnosed with SCST induced by CAM. As a result, the generalizability of these findings to wider populations or diverse clinical contexts, such as SCST with bacterial causes or patients without a previous history of COVID-19, may be constrained. Moreover, out-of-hospital follow-ups were not evaluated in this study.

Prospective and larger studies are required to determine whether AC is associated with reduced SCST mortality or morbidity, as well as to identify the optimal treatment regimens. However, while we encourage future studies to consider using RCTs or propensity score matching to mitigate the potential bias introduced by this non-randomized assignment, conducting studies with a sufficient sample size for such a rare condition, designed specifically to answer this question, will be exceedingly labor- and time-intensive and extremely unlikely to take place. Subsequently, while deciding on the most effective treatment approaches, neurologists must still rely on expert opinions and evidence from retrospective studies.¹ In our retrospective study, we carefully considered and addressed all sources of potential bias or imprecision (please see the "Materials and Methods" section). Notably, since we relied on objective medical records for data collection, the possibility of recall bias is minimized, as the data is documented contemporaneously without reliance on memory. Altogether, despite its drawbacks, we believe our observations contribute to the limited body of evidence in this field.

Conclusion

AC use in the management of SCST remains highly controversial. Our observations indicated no considerable difference between AC receivers and non-receivers in either mortality or morbidity of SCST. Additionally, survivors and non-survivors, as well as patients with complete recovery and those surviving with disability did not significantly differ in terms of AC-related characteristics (i.e., receiving AC, AC type, early AC initiation, and in-hospital AC therapy duration). However, it is necessary to keep in mind that statistical power declines with decreasing sample size, necessitating a cautious approach to the interpretation of results due to the diminished ability to identify true differences across groups. With respect to the limited evidence and scattered nature of this field of research, a thorough systematic review (and meta-analysis, if applicable) of studies evaluating AC in SCST

management from its inception to date would be fruitful to address a variety of debatable questions in this regard.

Conflict of Interests

The authors declare no conflict of interest in

this study.

Acknowledgments

We would like to thank all the patients and clinicians who made this study possible.

References

- Caranfa JT, Yoon MK. Septic cavernous sinus thrombosis: A review. *Surv Ophthalmol* 2021; 66(6): 1021-30.
- Kojan S, Al-Jumah M. Infection related cerebral venous thrombosis. *J Pak Med Assoc* 2006; 56(11): 494-7.
- Southwick F. Septic Dural Sinus Thrombosis [Online]. [cited 2020 Nov 20]; Available from: URL: <https://www.uptodate.com/contents/septic-dural-sinus-thrombosis#:~:text=Septic%20dural%20sinus%20thrombosis%20is,during%20his%20or%20her%20career>
- Jacob MS, Gunasekaran K, Miraclin AT, Sadiq M, Kumar CV, Oommen A, et al. Clinical profile and outcome of patients with cerebral venous thrombosis secondary to bacterial infections. *Ann Indian Acad Neurol* 2020; 23(4): 477-81.
- Weerasinghe D, Lueck CJ. Septic cavernous sinus thrombosis: Case report and review of the literature. *Neuroophthalmology* 2016; 40(6): 263-76.
- World Health Organization. WHO COVID-19 dashboard [Online]. [cited 2022 Feb 28]; Available from: URL: <https://data.who.int>
- Zali A, Khodadoost M, Gholamzadeh S, Janbazi S, Piri H, Taraghikah N, et al. Mortality among hospitalized COVID-19 patients during surges of SARS-CoV-2 alpha (B.1.1.7) and delta (B.1.617.2) variants. *Sci Rep* 2022; 12(1): 18918.
- Jameie M, Safarian NM, Mansouri P, Jalali A, Aghajani F, Lotfi-Tokaldany M, et al. The impact of the COVID-19 pandemic on hospitalization rates due to prosthetic valve thrombosis. *J Tehran Heart Cent* 2023; 18(2): 136-41.
- Soheili A, Khani S, Montazeri S, Shayegh A, Haji Miragha M, Jameie MS, et al. COVID-19 and acute kidney injury presentation; stages and prognosis. *J Prev Epidemiol* 2021; 6(1): e15.
- Majidi F, Mohagheghi Dare Ranj A, Jameie M, Jameie M, Mansouri P, Varpaei HA, et al. The relationship between cardiological parameters and PCR in patients with coronavirus infection: A cross-sectional study. *Medicine (Baltimore)* 2022; 101(50): e31935.
- Wang C, Tee M, Roy AE, Fardin MA, Srichokchatchawan W, Habib HA, et al. The impact of COVID-19 pandemic on physical and mental health of Asians: A study of seven middle-income countries in Asia. *PLoS One* 2021; 16(2): e0246824.
- Duden GS, Reiter J, Pasweg A, Weibelzahl S. Mental health of healthcare professionals during the ongoing COVID-19 pandemic: A comparative investigation from the first and second pandemic years. *BMJ Open* 2023; 13(3): e067244.
- Borhany H, Golbabaie S, Jameie M, Borhani K. Moral decision-making in healthcare and medical professions during the COVID-19 pandemic. *Trends in Psychol* 2023; 31(1): 210-30.
- Rafati A, Pasebani Y, Jameie M, Yang Y, Jameie M, Ilkhani S, et al. Association of SARS-CoV-2 vaccination or infection with bell palsy: A systematic review and meta-analysis. *JAMA Otolaryngol Head Neck Surg* 2023; 149(6): 493-504.
- Harirchian MH, Ghabae M, Sarraf P, Ranji-Burachaloo S, Agah E, Mousavi SV, et al. Nervous system involvement in hospitalized patients with COVID-19: Clinical and laboratory associations with poorer outcomes. *Infect Dis Clin Pract* 2023; 32(1): e1332.
- Jameie M, Togha M, Azizmohammad LM, Jafari E, Yazdan PM, Hemmati N, et al. Characteristics of headaches attributed to SARS-CoV-2 vaccination and factors associated with its frequency and prolongation: A cross-sectional cohort study. *Front Neurol* 2023; 14: 1214501.
- Sen M, Lahane S, Lahane TP, Parekh R, Honavar SG. Mucor in a viral land: A tale of two pathogens. *Indian J Ophthalmol* 2021; 69(2): 244-52.
- Sarkar S, Gokhale T, Choudhury SS, Deb AK. COVID-19 and orbital mucormycosis. *Indian J Ophthalmol* 2021; 69(4): 1002-4.
- Mehta S, Pandey A. Rhino-orbital mucormycosis associated with COVID-19. *Cureus* 2020; 12(9): e10726.
- Joshi S, Telang R, Tambe M, Havaladar R, Sane M, Shaikh A, et al. Outbreak of mucormycosis in coronavirus disease patients, Pune, India. *Emerg Infect Dis* 2022; 28(1): 1-8.
- Garg S, Masheshwari D, Bhushan B, Sardana V, Jain RK. Covid-19 and mucormycosis superinfection: prospective, observational study in a single center. *Ann Indian Acad Neurol* 2022; 25(3): 441-8.
- Mahalaxmi I, Jayaramayya K, Venkatesan D, Subramaniam MD, Renu K, Vijayakumar P, et al. Mucormycosis: An opportunistic pathogen during COVID-19. *Environ Res* 2021; 201: 111643.
- Rocha ICN, Hasan MM, Goyal S, Patel T, Jain S, Ghosh A, et al. COVID-19 and mucormycosis syndemic: Double health threat to a collapsing healthcare system in India. *Trop Med Int Health* 2021; 26(9): 1016-8.
- Singh AK, Singh R, Joshi SR, Misra A. Mucormycosis in COVID-19: A systematic review of cases reported worldwide and in India. *Diabetes Metab Syndr* 2021; 15(4): 102146.
- Sen M, Honavar SG, Bansal R, Sengupta S, Rao R, Kim U, et al. Epidemiology, clinical profile, management, and outcome of COVID-19-associated rhino-orbital-cerebral mucormycosis in 2826 patients in India - Collaborative OPAI-IJO Study on Mucormycosis in COVID-19 (COSMIC), Report 1. *Indian J Ophthalmol* 2021; 69(7): 1670-92.
- Avatef FM, Rezaei L, Javadirad E, Iranfar K, Khosravi A, Amini SJ, et al. Increased incidence of rhino-orbital mucormycosis in an educational therapeutic hospital during the COVID-19 pandemic in western Iran: An observational study. *Mycoses* 2021; 64(11): 1366-77.
- Pakdel F, Ahmadikia K, Salehi M, Tabari A, Jafari R, Mehrparvar G, et al. Mucormycosis in patients with COVID-19: A cross-sectional descriptive multicentre study from Iran. *Mycoses* 2021; 64(10): 1238-52.
- Kulkarni R, Pujari S. COVID-19-associated mucormycosis: What neurologists should know? *Ann Indian Acad Neurol* 2022; 25(3): 330-1.
- Cox GM. Mucormycosis (zygomycosis) [Online]. [cited 2023 Jan 22]; Available from: URL: [https://www.uptodate.com/contents/mucormycosis-zygomycosis?search=Mucormycosis%20\(zygomycosis\)&source=search_result&selectedTitle=1~70&usage_type=default&display_rank=1](https://www.uptodate.com/contents/mucormycosis-zygomycosis?search=Mucormycosis%20(zygomycosis)&source=search_result&selectedTitle=1~70&usage_type=default&display_rank=1)
- Khacha A, Bouchal S, Ettabyaoui A, Haloua M, Lamrani YA, Boubbou M, et al. Cavernous sinus thrombosis in a COVID-19 patient: A case report. *Radiol Case Rep* 2021; 16(3): 480-2.
- Padma Srivastava MV, Vishnu VY, Pandit AK. Mucormycosis epidemic and stroke in India during the COVID-19 pandemic. *Stroke* 2021; 52(10): e622-e623.
- Nehara HR, Puri I, Singhal V, Ih S, Bishnoi BR, Sirohi P. Rhinocerebral mucormycosis in COVID-19 patient with diabetes a deadly trio: Case series from the north-western part of India. *Indian J Med Microbiol* 2021; 39(3): 380-3.
- Dubey S, Mukherjee D, Sarkar P, Mukhopadhyay P, Barman D, Bandopadhyay M, et al. COVID-19 associated rhino-orbital-cerebral mucormycosis: An observational study from Eastern India, with special emphasis on neurological spectrum. *Diabetes Metab Syndr* 2021; 15(5): 102267.

34. Bhatia K, Jones NS. Septic cavernous sinus thrombosis secondary to sinusitis: are anticoagulants indicated? A review of the literature. *J Laryngol Otol* 2002; 116(9): 667-76.
35. Desa V, Green R. Cavernous sinus thrombosis: Current therapy. *J Oral Maxillofac Surg* 2012; 70(9): 2085-91.
36. Southwick FS, Richardson EP, Swartz MN. Septic thrombosis of the dural venous sinuses. *Medicine (Baltimore)* 1986; 65(2): 82-106.
37. Pirkey WP. Thrombosis of the cavernous sinus. *Arch Otolaryngol* (1925) 1950; 51(6): 917-24.
38. Sheikhi F, Yousefian N, Tehranipoor P, Kowsari Z. Estimation of the basic reproduction number of Alpha and Delta variants of COVID-19 pandemic in Iran. *PLoS One* 2022; 17(5): e0265489.
39. World Medical Association. World Medical Association Declaration of Helsinki: Ethical principles for medical research involving human subjects. *JAMA* 2013; 310(20): 2191-4.
40. Yu IT, Tse SL. Workshop 3--source of bias in case series, patient cohorts, and randomised controlled trials. *Hong Kong Med J* 2011; 17(6): 478-9.
41. Caliendo AM, Hanson KE. COVID-19: Diagnosis [Online]. [cited 2023 Feb 6]; Available from: URL: <https://www.uptodate.com/contents/covid-19-diagnosis>
42. Chakravarty J, Gupta MK, Tilak R, Kumar R, Maurya RP, Kumar N, et al. COVID-19-associated Mucormycosis: A clinico-epidemiological study. *J Diabetes Complications* 2022; 36(9): 108284.
43. Quinn TJ, Dawson J, Walters MR, Lees KR. Functional outcome measures in contemporary stroke trials. *Int J Stroke* 2009; 4(3): 200-5.
44. Levine SR, Twyman RE, Gilman S. The role of anticoagulation in cavernous sinus thrombosis. *Neurology* 1988; 38(4): 517-22.
45. National Institutes of Health. Clinical Spectrum of SARS-CoV-2 Infection [Online]. [cited 2022 Jun 6]; Available from: URL: <https://www.covid19treatmentguidelines.nih.gov/overview/clinical-spectrum/>
46. Munjal M, Khurana AS. Fungal infections and cavernous sinus thrombosis. *Indian J Otolaryngol Head Neck Surg* 2004; 56(3): 235-7.
47. Li DM, Shang PP, Zhu L, De Hoog GS. Rhino-orbital-cerebral mycosis and cavernous thrombosis. *Eur J Inflamm* 2014; 12(1): 1-10.
48. Gelston CD, Durairaj VD, Simoes EA. Rhino-orbital mucormycosis causing cavernous sinus and internal carotid thrombosis treated with posaconazole. *Arch Ophthalmol* 2007; 125(6): 848-9.
49. Kulkarni R, Misra UK, Meshram C, Kochar D, Modi M, Vishnu VY, et al. Epidemic of mucormycosis in COVID-19 pandemic: A position paper. *Ann Indian Acad Neurol* 2022; 25(1): 7-10.
50. Yadav S, Bs N, Ak S. Clinical profile of central nervous system involvement in patients with rhino orbital cerebral mucormycosis. *J Assoc Physicians India* 2022; 70(4): 11-2.
51. van der Poel NA, Mourits MP, de Win MML, Coutinho JM, Dijkers FG. Prognosis of septic cavernous sinus thrombosis remarkably improved: A case series of 12 patients and literature review. *Eur Arch Otorhinolaryngol* 2018; 275(9): 2387-95.
52. Paybast S, Mohamadian R, Emami A, Jameie M, Shahrab F, Zamani F, et al. Safety and efficacy of endovascular thrombolysis in patients with acute cerebral venous sinus thrombosis: A systematic review. *Interv Neuroradiol* 2022; 15910199221143418. [Online ahead of print].
53. Wang YH, Chen PY, Ting PJ, Huang FL. A review of eight cases of cavernous sinus thrombosis secondary to sphenoid sinusitis, including a 12-year-old girl at the present department. *Infect Dis (Lond)* 2017; 49(9): 641-6.
54. Rebelo J, Nayan S, Choong K, Fulford M, Chan A, Sommer DD. To anticoagulate? Controversy in the management of thrombotic complications of head & neck infections. *Int J Pediatr Otorhinolaryngol* 2016; 88: 129-35.
55. Funamura JL, Nguyen AT, Diaz RC. Otogenic lateral sinus thrombosis: Case series and controversies. *Int J Pediatr Otorhinolaryngol* 2014; 78(5): 866-70.
56. Shah UK, Jubelirer TF, Fish JD, Elden LM. A caution regarding the use of low-molecular weight heparin in pediatric otogenic lateral sinus thrombosis. *Int J Pediatr Otorhinolaryngol* 2007; 71(2): 347-51.