



Received: 13 Sep. 2023  
Accepted: 09 Nov. 2023

# Tinnitus and reduced word recognition with a bilateral inferior colliculus infarction after cerebellar arteriovenous malformation embolization

Nazila Malekian, Asker Ghorbani

Department of Neurology, Shariati Hospital, Tehran University of Medical Sciences, Tehran, Iran

## Keywords

Cerebellar; Arteriovenous Malformations; Embolization; Stroke; Inferior Colliculus; Word Deafness

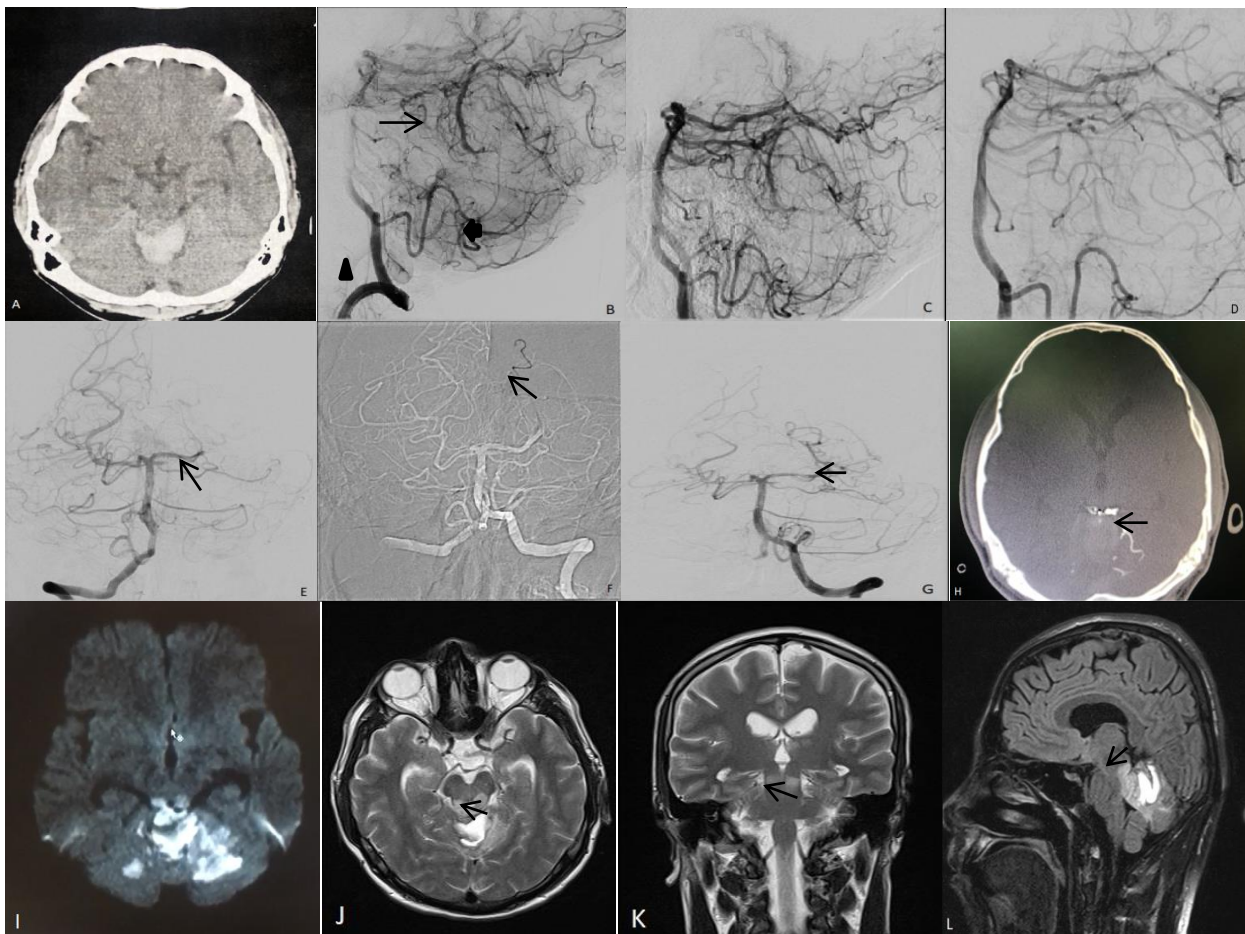
Cerebellar arteriovenous malformations (CAVMs) have increased probabilities of rupture and bleeding compared with arteriovenous malformations (AVMs) in other locations of the brain. The treatment of CAVMs includes craniotomy, endovascular treatment (EVT), radiotherapy, or a combination of multiple methods. EVT has been used in an increasing number of CAVM cases and is difficult, as the angioarchitecture of CAVMs is complex, consisting of the feeding artery, nidus, draining vein, and aneurysm on the feeding artery and in the nidus. EVT may be associated with complications, due to the involvement of important structures, such as the brainstem.<sup>1</sup> In the majority of the patients with

midbrain stroke, the infarctions are located in the ventral and tegmental portion of the mesencephalon and rarely involve the tectum and collicular areas.<sup>2</sup> In stroke patients, hypoacusia is extremely rare due to the organization of the central auditory pathways, which consist of more nuclei intercalated and extensive interconnections among them. Almost all ascending auditory fibers synapse in the inferior colliculus (IC) both ipsi- and contra-laterally.<sup>3</sup> The proximal superior cerebellar artery (SCA) has perforating branches that supply blood to the rostral cerebellum and brainstem, and anastomotic channels exist between the collicular branch of the posterior cerebral artery (PCA) and the medial terminal stem of the SCA.<sup>3</sup>

**How to cite this article:** Malekian N, Ghorbani A. Tinnitus and reduced word recognition with a bilateral inferior colliculus infarction after cerebellar arteriovenous malformation embolization. *Curr J Neurol* 2024; 23(1): 83-5.

Our case was a 30-year-old man admitted to a hospital in the north of the country due to severe headache, ataxia, nausea and vomiting, and neck pain from two weeks before his hospitalization. The patient was diagnosed with a cerebellar hemorrhage and transferred to another hospital in the north, where he was referred to our hospital a few days later. On brain computed tomography (CT), he had a cerebellar hemorrhage (Figure 1 A) and on examination, he was alert and had headache, slight imbalance, and impaired tandem gait without redor. The patient underwent cerebral angiography with diagnosis of CAVM. Digital subtraction angiography (DSA) of the left

vertebral artery showed that the AVM was supplied by the SCA (Figure 1 B, C). The draining vein was not seen in PCA microinjection; therefore, it did not have a PCA feeder. In SCA microinjection, a draining vein was seen that had diffuse and narrow feeders, emptying into deep veins, the precentral, and then Galen vein. Onyx was then injected from a micro catheter near the fistula site, distal of SCA. There were no feeding artery aneurysms. Extravasation was then happened at the AVM's perforated site and complete total obliteration of draining vein was done with embolization through left and right SCAs (Figure 1 D).



**Figure 1.** Computed tomography (CT) scan showing a hyper dense hemorrhagic lesion in the vermis (A); digital subtraction angiography (DSA) of the left vertebral artery showing the draining vein (arrow) supplied by the superior cerebellar artery (SCA) (arrowhead) from lateral view (B); DSA of the left vertebral artery showing the draining vein from oblique view (C); DSA after embolization showing complete total obliteration of arteriovenous malformation (AVM) (D); DSA showing occlusion of left posterior cerebral artery (PCA) (arrow) after embolization with Onyx (E); embolectomy of left PCA with catheter and wire (arrow) (F); DSA showing opening of left PCA (G); post-operative CT scan showing Onyx thrombosis through the SCA (H); post operation magnetic resonance imaging (MRI) of the patient, diffusion-weighted imaging (DWI) showing acute infarction in bilateral inferior colliculus (IC) and cerebellar hemispheres (I); axial T2-weighted image showing hyper intensity in bilateral IC (arrow) (J); coronal T2-weighted image showing hyper intensity in bilateral IC (arrow) (K); sagittal fluid attenuated inversion recovery (FLAIR) image showing hyper intensity in IC (arrow) and superior cerebellum (L)

Then occlusion of left PCA was seen (Figure 1 E), possibly due to an embolus that embolectomy was done with a catheter and wire (Figure 1 F, G). Choroidal arteries opened with poking and collicular artery was open. After cerebral angiography, patient suffered from tinnitus, reduced word recognition, and sleepiness which had acute infarction of bilateral IC and superior cerebellar in brain magnetic resonance imaging (MRI) with normal pure tone audiometry (Figure 1 L).

There have been few previous reports of the auditory effects of a lesion restricted to both ICs. In this report, we describe a patient with a lesion confined to the ICs who presented with tinnitus and reduced word recognition. There have been only 6 cases reported of the auditory effects of a lesion restricted to the ICs.<sup>4</sup> In 2 cases, the patients were completely deaf and audiometric data were not obtainable. In another case, who had the ICs resected on removal of a tectal plate glioma, speech comprehension deteriorated dramatically but pure-tone audiometry and brainstem auditory evoked potentials (BAEPs) remained normal. In other 2 cases described with bilateral and symmetrical lesions of the ICs, the word deafness occurred after a head injury for the first patient and after an AVM embolization for the second patient

with normal BAEPs. And the last case, a 43-year-old man with bilateral lesions of IC due to central nervous system (CNS) lymphoma was found to have relatively normal pure-tone averages with severely reduced bilateral word recognition scores. Our case resembled the last 4 cases in which pure-tone audition was retained with poor word discrimination scores. We suggest that Onyx may reflux via the anastomosis between collicular arteries of PCA and SCA. Therefore, to lower the risk of complications, a micro catheter should be advanced as close as possible to the fistula points to prevent penetration of the embolizer into the perforating branches. In conclusion, it appears that bilateral IC lesions may present with tinnitus, decreased word recognition, and preserved audition of pure tones. There is a few reports of bilateral IC infarction caused by intra-arterial Onyx injection. Therefore, we now present this complication in a patient with CAVM treated by EVT.

#### Conflict of Interests

The authors declare no conflict of interest in this study.

#### Acknowledgments

None.

#### References

1. Piao J, Luan T, Wang Y, Yu J. Imaging characteristics and endovascular treatment strategy for cerebellar arteriovenous malformations. *Med Int (Lond)* 2021; 1(3): 5.
2. Kim JS, Kim J. Pure midbrain infarction: Clinical, radiologic, and pathophysiologic findings. *Neurology* 2005; 64(7): 1227-32.
3. Zhang J, Lv X, Jiang C, Li Y, Wu Z. Superior cerebellar artery infarction in endovascular treatment for tentorial dural arteriovenous fistulas. *Eur J Radiol* 2010; 74(3): e33-e37.
4. Hoistad DL, Hain TC. Central hearing loss with a bilateral inferior colliculus lesion. *Audiol Neurootol* 2003; 8(2): 111-3.