



Bilateral anterior capsulotomy in a patient with severe obsessive-compulsive disorder: Case report

Received: 09 Mar. 2024
Accepted: 03 May 2024

Sajad Shafiee¹, Abbas Tafakhori^{2,3}, Mohammad Sadra Nemati⁴, Saeed Kargar-Soleimanabad^{5,6}, Sobhan Alipour-Kiasar⁷, Reza Yazdani-Cherati¹, Ahmadreza Hojati-Marvast², Omid Ahmadvand¹

¹ Department of Neurosurgery, Imam Khomeini Hospital Complex, Mazandaran University of Medical Sciences, Sari, Iran

² Department of Neurology, School of Medicine, Imam Khomeini Hospital Complex, Tehran University of Medical Sciences, Tehran, Iran

³ Iranian Center of Neurological Research, Tehran University of Medical Sciences, Tehran, Iran

⁴ School of Medicine, Tehran Medical Science Branch, Islamic Azad University, Tehran, Iran

⁵ Student Research Committee, Mazandaran University of Medical Sciences, Sari, Iran

⁶ Department of Neurosurgery, School of Medicine, Mazandaran University of Medical Sciences, Sari, Iran

⁷ Department of Electrical Engineering, School of Engineering, Lahijan Branch, Islamic Azad University, Lahijan, Iran

Keywords

Anterior Capsulotomy; Obsessive-Compulsive Disorder; Surgery; Psychosurgery; Case Reports

Obsessive-compulsive disorder (OCD) is a long-lasting condition in which a person experiences uncontrollable and recurring thoughts (obsessions), engages in repetitive behaviors (compulsions), or both. Individuals with OCD have time-consuming symptoms that can cause significant distress or interfere with daily life. Various treatment methods are available for OCD, including pharmacotherapy and psychosurgery. The use of surgical methods depends on the severity of the disorder, which is measured and evaluated using the Yale-Brown Obsessive Compulsive Scale (Y-BOCS).¹

The Y-BOCS is the most commonly used measure for assessing OCD. It is a semi-structured

interview that consists of a checklist of common obsessions and compulsions, along with a 10-item measure of symptom severity, which evaluates severity regardless of symptom subtype. A self-report version of the scale is also available. Total scores on the measure range from 0 to 40, with a score of 0-7 indicating subclinical symptoms, 8-15 indicating mild symptoms, 16-23 indicating moderate symptoms, 24-31 indicating severe symptoms, and 32-40 indicating extreme symptoms. The scale can also provide separate subscale scores for obsessions and compulsions (range: 0-20).²

How to cite this article: Shafiee S, Tafakhori A, Nemati MS, Kargar-Soleimanabad S, Alipour-Kiasar S, Yazdani-Cherati R, et al. Bilateral anterior capsulotomy in a patient with severe obsessive-compulsive disorder: Case report. *Curr J Neurol* 2024; 23(3): 193-6.

In the treatment of OCD, several different methods are available, with cognitive behavioral therapy (CBT) and pharmacotherapy being proposed as the first steps in treatment. In drug-resistant cases, alternative methods such as surgical interventions may be considered. The Y-BOCS serves as a valuable quantitative tool for assessing the severity of the disorder. When the severity of the disorder does not change or increases despite pharmacotherapy and occupational therapy, we may consider psychosurgery.³

Surgery for OCD is used for patients with the most severe forms of the disease when pharmacological and other psychotherapeutic alternatives have been ineffective. The main inclusion criteria for surgery include a minimum trial of three medications, 20 sessions of CBT (or failed CBT), and a Y-BOCS score of 24 or above. The four different targets currently being used are the anterior capsule, cingulate gyrus (CG), subcaudate tractotomy, and limbic leucotomy. The nucleus accumbens is another promising target for this surgery. Two methods of surgery are employed to alter these targets: one involves creating lesions, while the other involves stimulating these targets using deep brain stimulation (DBS). In the lesioning method, radiofrequency is used to produce a thermal lesion of calculated volume, which is permanent and irreversible.⁴

There is a convergence of evidence implicating the cortico-striato-thalamo-cortical (CSTC) loop, which involves the orbitofrontal cortex (OFC), anterior cingulate cortex (ACC), and basal ganglia, as central to the pathophysiology of OCD. Two distinct routes are conceptualized from the striatum to the thalamus: the so-called "direct" and "indirect" pathways. The direct pathway projects from the cortex to the striatum, then to the internal segment of the globus pallidus (GP) and substantia nigra (SN), and finally to the thalamus before returning to the cortex. The indirect pathway follows a similar route from the cortex to the striatum but then projects to the external segment of the GP and the subthalamic nucleus, before returning to the internal segment of the GP/SN, where it joins the direct pathway to the thalamus and projects back to the cortex. Impulses transmitted via the direct pathway disinhibit the thalamus, presumably resulting in a release of behaviors necessary for adaptive functioning.⁵ Activity in the indirect pathway inhibits the thalamus, leading to the cessation of ongoing behavioral routines. The prevailing theory on OCD

suggests that an as-yet-unknown primary striatal pathological process underlies a relative imbalance favoring striato-thalamic inhibition, which leads to hyperactivity within the OFC, ACC, caudate nucleus (CN), and thalamus. Additionally, the prefrontal cortex (PFC), cingulate cortex, limbic circuit, OFC, hypothalamus, and amygdala are other structures that communicate with these primary circuits through various feedback loops. This forms the basis for various target sites for treating OCD.⁶ An anterior capsulotomy (AC) is one of the last therapeutic options for OCD that is refractory to conservative treatments. Several forms of cognitive dysfunction have been identified after assessing neuropsychological outcomes in patients with OCD; however, few studies have focused on cognitive changes in these patients after surgery.⁵ AC is a safe, well-tolerated, and efficacious therapy. Its underuse is likely a result of historical prejudice rather than a lack of clinical effectiveness.⁷

The patient was a 27-year-old single man with a degree in software engineering who suffered from severe obsession [based on the Diagnostic and Statistical Manual of Mental Disorders, Fifth Edition (DSM-V)]. The initial symptoms which started from the age of 9 were a lot of orders in the arrangement of the room, bed, and tables, as well as frequent checking of his appearance and clothes in the mirror. He always checked his various tools and objects and placed each tool in its proper place. Along with these symptoms, he always checked the charging of his mobile phone and laptop and was very sensitive to its changes. He was always dissatisfied with his low weight and body morphology. The symptoms started in elementary school, he did not like his class teacher, but he was very good at his studies. He cared a lot about orders and he had a strong obsession with orders. He was not treated until he was 16 years old, and since then he has been treated by several psychiatrists. Patient's characteristics are summarized in table 1.

Since the age of 17, with the intensification of the anxiety of the final exams, his obsessive symptoms increased in the form of negative intrusive thoughts and excessive checking behaviors, and for the first time at this age, he went to a psychiatrist for professional help. Moreover, in 2012, he tried to commit suicide with the rat poison, but he did not succeed and was saved. The patient has not been taking his medication since October 2022; he was not aggressive, and was often introverted and had no patience. He was prescribed fluvoxamine and clomipramine and continued the drug treatment regularly.

Table 1. Patient characteristics

Variable	
Gender	Man
Age (year)	27
Marriage	Single
Illness duration (year)	18
Drug trials	Fluvoxamine, fluoxetine, citalopram, sertraline, sodium valproate, olanzapine, aripiprazole, risperidone
Drug-usage pre-operation	No drug
Family history	Severe OCD in brother

OCD: Obsessive-compulsive disorder

After some time, risperidone at a dose of 4 mg and aripiprazole at a dose of 15 mg were added to the initial treatment. The other augmentation drug was olanzapine 15 mg and sodium valproate 1200 mg daily. The patient had high medication compliance and has been following up on his treatment courses for the last 10 years and has also had a course of CBT for 20 sessions, but pharmacotherapy and psychotherapy have never led to improvement or reduction of his symptoms. He stopped taking medicines in the last 1 year.

On May 18, 2023, the patient participated in pharmacotherapy; he was not actively present. On May 20, 2023, the practical OCD scale was implemented and it scored 33 in the interpretation, which was placed in the extreme obsession scale. Besides, on the same date, the Minnesota Multiphasic Personality Inventory (MMPI) test was performed and the patient answered all the questions and used the eraser three times. In general, the patient felt helpless, isolated, psychologically disturbed, and uncomfortable, annoyed easily, and complained of insomnia. He had ritual problems and felt angry and hateful. Additionally, he used projection defense mechanisms. There is a lot of emotional turmoil in the interpretation of a point. He had many emotions such as depression, suicidal thoughts, pessimism, worry, and health-related problems. He was characterized by rumination and thinking and a feeling of inadequacy.

On May 21, 2023, the patient participated in group therapy; he did not participate actively, but he listened to the discussions. Moreover, some dysfunctional solutions were treated, for example, addiction, avoidance of aggression, as well as behavior activation steps. Some behaviors were taught in this patient, and several incorrect behaviors that aggravated his diseases were

corrected. Behavioral techniques of low mood management were practiced in a group, and the role of thoughts in creating and aggravating his mental illnesses was investigated.

The patient's mood changed, and he felt hopeless, sad, and bored for a few days, but then he experienced an increase in mood, energy, and sexual desire. Currently, the patient does not have suicidal thoughts or despair, does not have hallucinations, loss, or pessimism, and mentions good sleep and appetite. Following the lack of therapeutic response to pharmacotherapy, the patient underwent surgery on June 30, 2023, and at the time of hospitalization, his obsession score was 33 on the Y-BOCS and in the category of very severe obsession. The current study has been reported in line with the Surgical Case Report (SCARE) criteria.⁸

Surgical Technique: A preoperative planning magnetic resonance imaging (MRI) was performed 1 day before surgery. T2-weighted coronal images were used to identify the internal capsule. A surgical target, 3 mm anterior to the posterior border of the anterior commissure (AC) and 2 mm inferior to the AC-posterior commissure (AC-PC) plane was selected. This was the bottom of the target. On the day of surgery, after installing the Leksell frame following local anesthesia, the patient was moved to computed tomography (CT) scan and then underwent surgery.

A stereotactic CT scan was performed and merged with the preoperative MRI. The target was approached through a pre-coronal twist drill under local anesthesia. The neurophysiological response was noted starting from 20 mm above the target to 3 mm below the target on the right side and from 15 mm above to 3 mm below the target on the left side. Radiofrequency lesioning was done bilaterally at 75 °C for 60 seconds; in the end, the entry point was sutured. In the recovery room, he was in good condition. After one day, he got discharged.

This patient was suffering from OCD and came to us after stopping the medicine and increasing the symptoms of the disease. At first, he was treated with psychotherapy, but no change was achieved. After no change in behavior and symptoms, he underwent surgery. The severity of the symptoms of the disease was high; therefore, we decided to perform our last option, surgery in the AC area. After determining the location of the lesion and stimulating the desired point in the AC area, the surgery was completed and with the passing of 3 months, the severity of the disease decreased from

33 to 20 based on the Y-BOCS scale, which means that the patient's obsession and anxiety decreased and the patient's behavior improved.

After 2 weeks and 1, 3, and 6 months later, the patient was visited again. One month after discharge from the hospital, he was re-evaluated for obsessive-compulsive symptoms. The clinical symptoms were reduced and the Y-BOCS score was reported as 20. He had no longer felt helpless, carried a lot about orders, and no longer suffered from insomnia. What makes this case unique for case presenting is dramatical responses to AC in a short period, decreased by 13 points based on the Y-BOCS scale in one month after surgery, and this was one of the first cases in the Middle East who was treated by AC.

Several surgeons compared capsulotomy and cingulotomy and observed that capsulotomy gave better results compared to cingulotomy.⁹ In fact, they observed both the safety of the surgery and a better treatment result.¹⁰ Besides, the researchers found that the correct placement of the right AC lesion compared to the left AC lesion would have a better treatment result.¹¹ Based on other research, they proved that capsulotomy could be a safe procedure for those who had OCD disease.¹²

In this case, surgery increases the chance of treatment, but which method of surgery is used depends on the condition of the patient and the severity of the disease. Considering the severity of the disease and the patient's condition, psychotherapy medication did not respond and our preference was for AC surgery. Our surgery result was perfect and he has been treated successfully. Signs of severe OCD were controlled

and treated. Post-operative T2-MRI shows lesions in the right and left anterior limb of the internal capsule/ventral striatum (Figure 1). After 3 months of follow-up, the family reported that his obsession was well controlled, and he had less anxiety and depression.

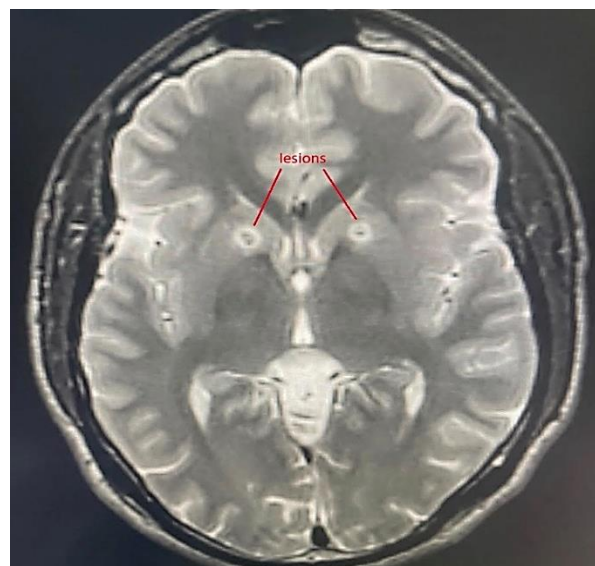


Figure 1. Post-operative T2-magnetic resonance imaging (MRI)

Conflict of Interests

The authors declare no conflict of interest in this study.

Acknowledgments

The authors thank the staff of the Neurosurgery Unit Research Center, Imam Khomeini Hospital, Mazandaran University of Medical Sciences, Sari, Iran.

References

- Hazen EP, Reichert EL, Piacentini JC, Miguel EC, do Rosario MC, Pauls D, et al. Case series: Sensory intolerance as a primary symptom of pediatric OCD. *Ann Clin Psychiatry* 2008; 20(4): 199-203.
- Koen N, Stein DJ. Obsessive-compulsive disorder. In: Michael J. Zigmond MJ, Lewis P, Rowland LP, Joseph T, Coyle JT, editors. *Neurobiology of brain disorders: Biological basis of neurological and psychiatric disorders*. San Diego, CA: Academic Press; 2015. p. 621-38
- Graghani A, Zaccari V, Femia G, Pellegrini V, Tenore K, Fadda S, et al. Cognitive-behavioral treatment of obsessive-compulsive disorder: The results of a naturalistic outcomes study. *J Clin Med* 2022; 11(10): 2762.
- Nauczyciel C, Robic S, Dondaine T, Verin M, Robert G, Drapier D, et al. The nucleus accumbens: a target for deep brain stimulation in resistant major depressive disorder. *J Mol Psychiatry* 2013; 1(1): 17.
- Doshi PK. Surgical treatment of obsessive compulsive disorders: Current status. *Indian J Psychiatry* 2009; 51(3): 216-21.
- de Koning PP, Figeo M, van den Munckhof P, Schuurman PR, Denys D. Current status of deep brain stimulation for obsessive-compulsive disorder: A clinical review of different targets. *Curr Psychiatry Rep* 2011; 13(4): 274-82.
- Kramska L, Urgosik D, Liscak R, Hreskova L, Skopova J. Neuropsychological outcome in refractory obsessive-compulsive disorder treated with anterior capsulotomy including repeated surgery. *Psychiatry Clin Neurosci* 2021; 75(3): 101-7.
- Agha RA, Franchi T, Sohrabi C, Mathew G, Kerwan A. The SCARE 2020 Guideline: Updating Consensus Surgical CAse REport (SCARE) Guidelines. *Int J Surg* 2020; 84: 226-30.
- Fodstad H, Strandman E, Karlsson B, West KA. Treatment of chronic obsessive compulsive states with stereotactic anterior capsulotomy or cingulotomy. *Acta Neurochir (Wien)* 1982; 62(1-2): 1-23.
- Laitinen LV, Singounas E. Intraoperative electrical stimulation of the brain in patients with obsessive-compulsive neurosis. *Appl Neurophysiol* 1988; 51(6): 317-23.
- Lippitz BE, Mindus P, Meyerson BA, Kihlstrom L, Lindquist C. Lesion topography and outcome after thermocapsulotomy or gamma knife capsulotomy for obsessive-compulsive disorder: Relevance of the right hemisphere. *Neurosurgery* 1999; 44(3): 452-8.
- Personality and neurosurgery. Proceedings of the third convention of the Academia Eurasiana Neurochirurgica. Brussels, August 30-September 2, 1987. *Acta Neurochir Suppl (Wien)* 1988; 44: 1-185.