



# A 58-year-old patient with acute lymphocytic leukemia with methotrexate-induced leukoencephalopathy

Received: 08 June 2024  
Accepted: 03 Aug. 2024

Marcos R. Flores<sup>1</sup>, Dianella Rente Lavastida<sup>2</sup>, Zachary I. Merhavy<sup>3</sup>, Maryam Ameen<sup>3</sup>, Samir Ruxmohan<sup>4</sup>

<sup>1</sup> Department of Clinical Sciences, University of Medicine and Health Sciences, Basseterre, St. Kitts & Nevis

<sup>2</sup> Department of Clinical Sciences, St. George's University, School of Medicine, True Blue, Grenada

<sup>3</sup> Department of Clinical Sciences, Ross University School of Medicine, Bridgetown Barbados

<sup>4</sup> Department of Neurology, Division of Neurocritical Care, University of Texas Southwestern Medical Center, Dallas, TX, USA

## Keywords

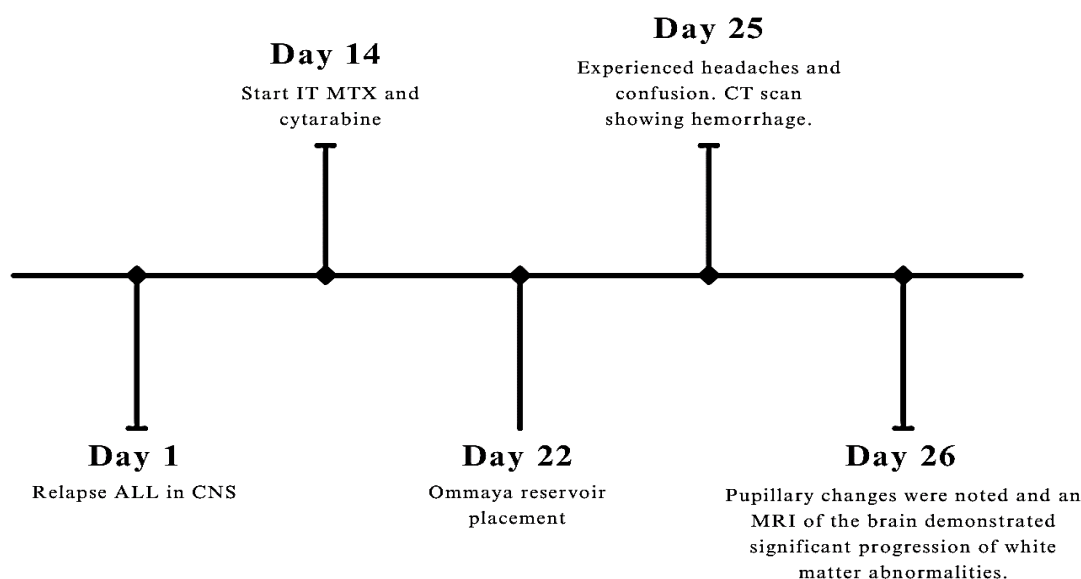
Methotrexate; Brain Disease; Cytarabine; Acute Lymphoblastic Leukemia; Spinal Injections; Neurotoxicity Syndromes

Methotrexate (MTX) is a folic acid antagonist and is one of the most commonly utilized chemotherapeutics in cancer treatment.<sup>1</sup> MTX-related neurotoxicity occurs in only 3.1%-3.8% of cases and manifests with acutely and clinically alarming symptoms.<sup>2</sup> These symptoms can be mistaken for other etiologies such as stroke, seizure, headache, and disorientation.<sup>2-5</sup> Due to the ambiguous presentation, differentiation and diagnosis are extremely critical yet incredibly challenging in an emergency department (ED) setting. This case will discuss the treatment and outcomes of a patient who was diagnosed with leukoencephalopathy due to MTX toxicity.

A 58-year-old male patient with a history of

hypertension (HTN), benign prostatic hyperplasia, and acute lymphocytic leukemia (ALL) with a Philadelphia chromosome presented to the ED with sudden anisocoria, impaired communication, disorientation, and an inability to follow commands consistently. Emergency head computed tomography (CT) imaging demonstrated a small tract hemorrhage along the Ommaya reservoir, where the magnetic resonance imaging (MRI) showed a progression in white matter abnormalities with extension into the caudal brainstem and cerebellar peduncles. He was subsequently admitted to the intensive care unit (ICU) for further management.

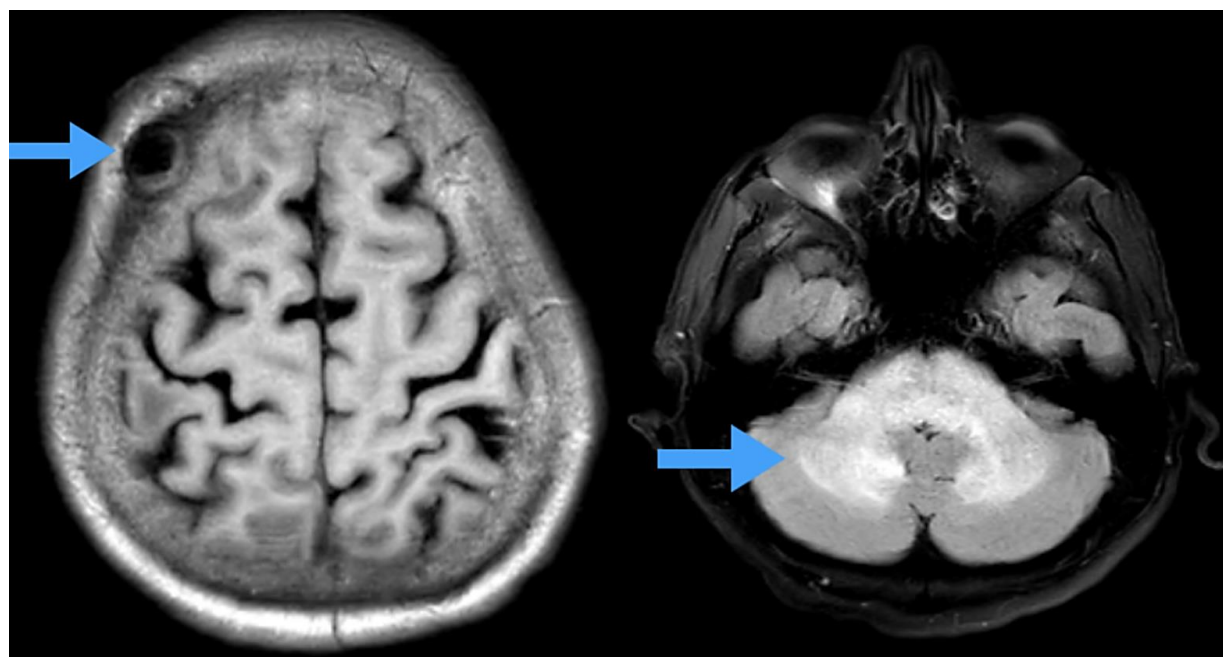
**How to cite this article:** Flores MR, Lavastida DR, Merhavy ZI, Ameen M, Ruxmohan S. A 58-year-old patient with acute lymphocytic leukemia with methotrexate-induced leukoencephalopathy. Curr J Neurol 2024; 23(4): 276-8.



**Figure 1.** Timeline showing the progression of symptoms

The patient was diagnosed with relapse ALL in the central nervous system (CNS) 26 days before symptoms (Figure 1). He started on an intrathecal (IT) MTX treatment and cytarabine 14 days after being diagnosed with ALL relapse, and eight days after the treatment, an Ommaya reservoir was placed to facilitate treatment (Figure 2). After three days of the reservoir being placed, he started developing headaches and confusion. His clinical presentation and MRI findings in the white matter

raised concern for MTX toxicity (Figure 2). Subsequently, the patient was admitted to the ICU and intubated due to respiratory failure. The treatment regimen for the patient consisted of discontinuing MTX, giving IT cytarabine, high-dose steroids, bone marrow transplant (BMT), and leucovorin (to treat the MTX toxicity) following BMT guidelines. Although the patient was treated aggressively, the family opted for palliative care due to a poor prognosis.



**Figure 2.** T2 fluid-attenuated inversion recovery (FLAIR) magnetic resonance imaging (MRI) demonstrating Ommaya procedure on the left and demonstrating diffusion restriction in the cerebellum due to methotrexate (MTX)-leukoencephalopathy on the right

Patients with cancer receiving chemotherapy are often at increased risk of neurological deficits due to etiologies such as infection, metabolic derangements, electrolyte abnormalities, and as in this case, drug-induced neurotoxicity.<sup>3</sup> Prior studies have noted that on MRI imaging, the neurotoxicity lacks correlation with the severity of symptoms, whereas a negative MRI cannot be assumed to be a lack of neurotoxicity.<sup>2</sup> This case is unique as the patient presented with sudden anisocoria, impaired communication, disorientation, and an inability to follow commands consistently with stroke symptoms along with a positive head T2 fluid-attenuated inversion recovery (FLAIR) MRI result (Figure 2).

The patient was started on an IT MTX treatment and cytarabine with Ommaya. IT MTX administration is sometimes chosen over others because it can reach the CNS more easily.<sup>2</sup> In patients treated with MTX, it is important to monitor for neurological deficits, especially in those presenting with stroke-like symptoms.<sup>2</sup> MTX neurotoxicity is rare, seen in 3.1%-3.8% of cases, but can manifest from days to years after treatment.<sup>2,3</sup> The clinical presentation of MTX neurotoxicity can be very variable and can be mistaken with other etiologies like stroke, seizure, headache, and disorientation.<sup>2-5</sup> As in this patient, there have been cases presenting with stroke-like symptoms that can be transient, unlike the symptoms of vascular strokes.<sup>3</sup> Although our patient did not have a good prognosis, there have been many cases where patients improved, emphasizing the importance of identifying and treating as soon as possible.<sup>3-5</sup>

MTX-induced leukoencephalopathy is often easily confused with acute ischemic strokes (AIS), which ultimately leads to taking the wrong treatment approach.<sup>6</sup> Some cases have reported opting for thrombolysis under the suspicion of an ischemic event.<sup>6</sup> Such cases aid in emphasizing the importance of recognizing the

clinical features of MTX neurotoxicity and then utilizing the proper diagnostic tools to proceed with appropriate management.

There is no definitive treatment for this condition; however, leucovorin with aminophylline are the usual agents used as rescue medication because they are well-tolerated.<sup>4,6</sup> The mode of action consists of rescuing normal cells from the toxic effects of MTX's inhibition as it is a competitive inhibitor of dihydrofolate reductase (DHFR).<sup>1,2</sup> Other studies have reported the use of methylprednisolone, dexamethasone, or dextromethorphan to reduce edema and improve symptoms overall.<sup>3,4,6</sup> However, more data are needed to draw a more definitive conclusion as how to manage the condition most effectively.

The current study emphasizes the importance of recognizing the critical signs of encephalopathy in patients treated with MTX. Patients undergoing chemotherapy for neoplastic conditions may present with acute neurological symptomatology for a variety of reasons. Because of this, patients with a stroke-like presentation should be emergently evaluated with an MRI to rule out stroke pathology. The reinitiation of MTX should be considered given the efficacy of the medication for the management of immune and oncological conditions.

### Conflict of Interests

The authors declare no conflict of interest in this study.

### Acknowledgments

We would like to extend our heartfelt gratitude to the Caribbean Research Group (CRG) for fostering meaningful connections between medical students and physicians across the United States, which made things like this possible. Special thanks to Dr. Ruxmohan for his trust, guidance, and unwavering support throughout this journey.

### References

1. Hanoodi M, Mittal M. Methotrexate. 2023 Aug 16. In: StatPearls [Internet]. Treasure Island, FL: StatPearls Publishing; 2024.
2. AlKawi A, Hanbali A, Haj AN, Mufti MA, Abdul RS. Recurrence of methotrexate-induced leukoencephalopathy after methotrexate rechallenge: A case report and literature review. *Radiol Case Rep* 2023; 18(3): 799-804.
3. Cruz-Carreras MT, Chافتari P, Shamsnia A, Guha-Thakurta N, Gonzalez C. Methotrexate-induced leukoencephalopathy presenting as stroke in the emergency department. *Clin Case Rep* 2017; 5(10): 1644-8.
4. Ganesan P, Bajpai P, Shah A, Saikrishnan P, Sagar TG. Methotrexate induced acute encephalopathy-occurrence on re-challenge and response to aminophylline. *Indian J Hematol Blood Transfus* 2014; 30(Suppl 1): 105-7.
5. Teshima K, Kume M, Kondo R, Shibata K, Abe K, Aono H, et al. Methotrexate-induced transient encephalopathy in an adolescent and young adult patient with acute lymphoblastic leukemia. *Intern Med* 2021; 60(13): 2115-8.
6. Panicker VV, Radhakrishnan SE, Kuruttukulam GV, Bose JA, Favas TT. Methotrexate-induced leukoencephalopathy as a clinical and radiological mimicker of acute ischemic stroke leading to thrombolysis. *Cureus* 2024; 16(1): e51542.