



# Delayed diagnosis of dopa-responsive dystonia initially attributed to syringomyelia: A case report

Received: 03 Mar. 2025  
Accepted: 04 May 2025

Seyed Amirhassan Habibi<sup>1</sup>, Fatemeh Moghadas<sup>2</sup>, Farhad Modara<sup>3</sup>, Gholamali Shahidi<sup>4</sup>, Nafiseh Mohebi<sup>1</sup>, Maryam Mehdizadeh<sup>5,6</sup>

<sup>1</sup> Department of Neurology, Hazrat Rasool-e Akram Hospital, Iran University of Medical Sciences, Tehran, Iran

<sup>2</sup> Neurology Research Center, Kerman University of Medical Sciences, Kerman, Iran

<sup>3</sup> Department of Neurology, School of Medicine, Ilam University of Medical Sciences, Ilam, Iran

<sup>4</sup> Department of Neurology, Firoozgar Hospital, Iran University of Medical Sciences, Tehran, Iran

<sup>5</sup> Cellular and Molecular Research Center, Iran University of Medical Sciences, Tehran, Iran

<sup>6</sup> Department of Neurosciences, School of Advanced Technologies in Medicine, Iran University of Medical Sciences, Tehran, Iran

## Keywords

Dystonia; Syringomyelia; Levodopa

Syringomyelia is a rare disorder, and its primary pathophysiology is cerebrospinal fluid (CSF) circulation dysfunction. A syrinx is a fluid-filled cyst or cavity within the spinal cord substance that leads to myelopathy.<sup>1</sup> Dystonia, a movement disorder characterized by abnormal posturing or repetitive movements due to sustained or intermittent muscle contractions,<sup>2</sup> can be a manifestation of syringomyelia, and it has been reported in plenty of literature.<sup>3</sup> However, when dystonia occurs in a patient with syringomyelia, it can be a diagnostic challenge, as attributing dystonic symptoms to the syrinx requires a completely different treatment approach.

In this paper, we introduce an adolescent girl

with syringomyelia and dystonia whose dystonic symptoms have been attributed to the syrinx for nine years. Still, a levodopa trial changed the therapeutic direction and saved her from unnecessary surgery. This case highlights the diagnostic challenges when dystonia and syringomyelia occur together and warns how misinterpreting symptoms can not only prevent patients from receiving the right medication but also lead to unnecessary interventions.

Our patient was a 15-year-old girl born into non-consanguineous parents with normal birth and development up to 6 years of age.

**How to cite this article:** Habibi SA, Moghadas F, Modara F, Shahidi G, Mohebi N, Mehdizadeh M. Delayed diagnosis of dopa-responsive dystonia initially attributed to syringomyelia: A case report. *Curr J Neurol* 2025; 24(3): 247-50.

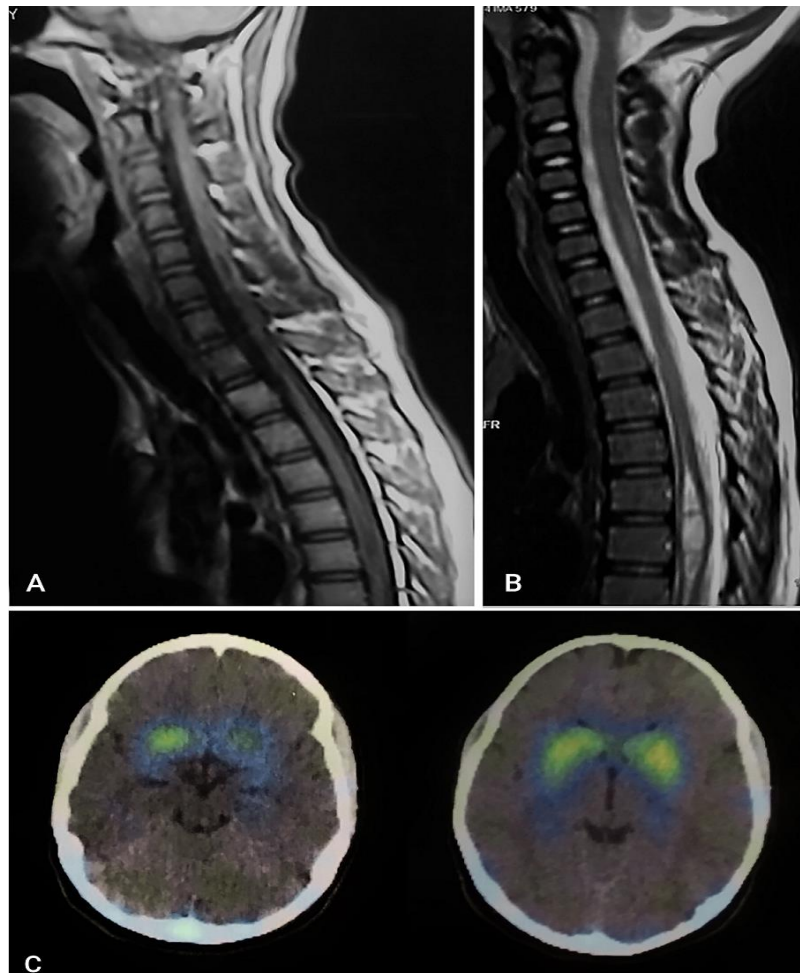
Thenceforth, her problems appeared insidiously in gait difficulties and neck posturing. There was no history of trauma, and family history was negative for any neurological or genetic diseases. She had received complete vaccination according to the national immunization program, and her past medical history was negative.

At that time, neurological examination revealed neck forward bending, mild lower limbs weakness, mild lower limbs spasticity, hyperreflexia, and loss of pain and temperature sensation along the arms and back. Neither muscle atrophy nor any precise sensory level was found. Her gait was mildly dystonic and spastic (Video 1). Brain and spinal cord magnetic resonance imaging (MRI) was performed as a part of a diagnostic workup. They showed longitudinal hyperintense signals on the T2-weighted images of the cervical

and thoracic cord, which were hypointense on the T1-weighted images, in accordance with syringomyelia (Figure 1, A and B).

Brain MRI was normal with no evidence of Chiari malformation. Therefore, the patient was conservatively followed as a case of syringomyelia. In follow-up visits, considering the worsening of gait and progression of neck posturing, decompression surgery was brought up as an option.

When we met the patient, she was frustrated and anxious. The systemic physical examination was unremarkable. Ophthalmologic evaluation revealed no presence of a Kayser-Fleischer ring. In the neurological exam, in addition to mild weakness and sensory signs (which had been previously noticed by her physician), excessive forward bending of the neck was also remarkable.



**Figure 1.** A and B) Sagittal images of cord magnetic resonance imaging (MRI) show the patient's syrinx as longitudinal hypointense signals on the T1-weighted sequence in cervical and thoracic levels, which are hyperintense on the T2-weighted sequence; C) Dopamine transporter imaging (DaTscan) of the patient shows normal striatal uptake.

The differential diagnosis for this condition includes one form of cervical dystonia and head drop. Neck strength measured in all directions was within normal range, and further examination revealed some repetitive movements and posturing of the head and neck while she was distracted. Therefore, we considered the neck forward bending as antecollis (a form of cervical dystonia). She reported no sensory trick. The muscle tone was increased, the cerebellar examination was normal, and the plantar reflexes were downward. The patient showed mild asymmetric bradykinesia, and her gait was dystonic.

According to the patient's history and neurological examination, our impression was dystonia. As in any case of early-onset dystonia, we performed a levodopa trial to check whether the dystonia was dopamine-responsive. Thus, we administered levodopa C 250 milligrams and domperidone. Half an hour later, her cervical posturing improved, and her gait dystonia almost disappeared. The severity of dystonia was assessed using the Burke-Fahn-Marsden Dystonia Rating Scale (BFMDRS). At baseline, the patient exhibited dystonia with a movement score of 16. Following levodopa treatment, the score decreased to 1, indicating substantial motor improvement. Therefore, we started levodopa C at a dose of 50 milligrams three times a day, and gradually increased it to 125 milligrams three times a day (with a levodopa equivalent daily dose of 375 milligrams/day). Her symptoms were well-controlled in the follow-up visits with no side effects (Video 2), and as might be expected, decompression surgery was not required anymore.

To rule out other causes of dystonia in this patient, serum and urine copper levels and serum ceruloplasmin levels were checked, and the results were normal. Considering mild bradykinesia, hypertonicity, and dystonia, with a dramatic response to levodopa, the differential diagnoses were narrowed to dopa-responsive dystonia (DRD) and juvenile Parkinson's disease (JPD). To differentiate between these two conditions, dopamine transporter imaging (DaTscan) was performed and showed normal striatal uptake, compatible with the diagnosis of DRD (Figure 1, C).

After four years of follow-up, the patient's dystonic symptoms have a sustained response to the same dose of levodopa C, and there was no need for any additional therapies or rehabilitation interventions.

DRD is a neurochemical disorder with both

clinical and genetic heterogeneity. Its main clinical features are childhood-onset dystonia, diurnal variation of symptoms, and an excellent and sustained response to low doses of levodopa.<sup>4</sup> DRD is often misdiagnosed, and reports show that its symptoms are frequently mistaken for other diseases, such as orthopedic conditions, hereditary spastic paraparesis, and epilepsy, with cerebral palsy (CP) as the most frequent one.<sup>5,6</sup> Early and accurate diagnosis requires awareness of the condition and the use of appropriate diagnostic tests, including a levodopa trial.<sup>7</sup>

When we met the patient, dystonia was the most prominent clinical finding, which was assumed to be caused by her syrinx. Even though weakness and sensory loss are the main symptoms of syringomyelia, there are several reports of abnormal movements as presentations of this disorder (including syringomyelia-associated dystonia). It is not clear if there is causality, and several possible pathophysiologies have been proposed. In some of the reported patients, dystonia has improved following decompression surgery; in one patient, surgery did not affect dystonia, and in two patients, dystonia has recurred following initial improvement.<sup>3</sup>

From a different point of view, we considered our patient as a case of early-onset dystonia. It is an essential step in young patients with dystonia to rule out DRD with a levodopa trial, based on the European Federation of Neurological Societies (EFNS) guidelines on diagnosis and treatment of primary dystonias. Our patient's dystonia had a dramatic response to a single dose of levodopa, and a maintenance dose of this drug made her symptom-free and saved her from unnecessary neurosurgical surgery. Here, we reported the first case of DRD whose treatment was delayed because of attributing her symptoms to a syrinx. As only one of the previous case reports of syringomyelia-associated dystonia mentioned levodopa administration, which was ineffective,<sup>8</sup> we cannot be sure whether other cases were dopa-responsive or not.

It should be mentioned that the lack of genetic testing is the main limitation of this report. The diagnosis was made based on the patient's dramatic and sustained response to levodopa, as well as nuclear imaging findings, rather than genetic confirmation.

Our patient had an informative course as she was untreated for nine years, and was so close to undergoing unnecessary surgery. This case

illustrates an interesting point: Although syringomyelia has been known as a rare cause of dystonia, DRD, as a treatable cause of this abnormal movement, even in apparent central nervous system (CNS) lesions, should be considered.

## References

1. Leclerc A, Matveeff L, Emery E. Syringomyelia and hydromyelia: Current understanding and neurosurgical management. *Rev Neurol (Paris)* 2021; 177(5): 498-507.
2. Albanese A, Bhatia K, Bressman SB, Delong MR, Fahn S, Fung VSC, et al. Phenomenology and classification of dystonia: a consensus update. *Mov Disord* 2013; 28(7): 863-73.
3. Mulroy E, Balint B, Latorre A, Schreglmann S, Menozzi E, Bhatia KP. Syringomyelia-Associated Dystonia: Case Series, Literature Review, and Novel Insights. *Mov Disord Clin Pract* 2019; 6(5): 387-92.
4. Salles PA, Terán-Jimenez M, Vidal-Santoro A, Chaná-Cuevas P, Kauffman M, Espay AJ. Recognizing Atypical Dopa-Responsive Dystonia and its Mimics. *Neurol Clin Pract* 2021; 11(6): e876-e84.
5. Jan MMS. Misdiagnoses in children with dopa-responsive dystonia. *Pediatr Neurol* 2004; 31(4): 298-303.
6. Weissbach A, Pauly MG, Herzog R, Hahn L, Halmans S, Hamami F, et al. Relationship of genotype, phenotype, and treatment in dopa-responsive dystonia: MDSGene review. *Mov Disord* 2022; 37(2): 237-52.
7. Wijemanne S, Jankovic J. Dopa-responsive dystonia—clinical and genetic heterogeneity. *Nat Rev Neurol* 2015; 11(7): 414-24.
8. Hwang YS, Lee SH, Jo S, Chung SJ. Syringomyelia Manifesting With Pseudodystonia: A Case Report. *J Mov Disord* 2021; 15(2): 175-7.

## Conflict of Interests

The authors declare no conflict of interest in this study.

## Acknowledgments

None.