DOI: *http://dx.doi.org/10.18502/cjn.v25i1.???*

Current Journal of Neurology

Original Paper

Curr J Neurol 2026; 25(1): 28-36

Complications of deep brain stimulation: A single-center survey

Received: 10 Sep. 2025
Accepted: 03 Nov. 2025

Mehri Salari[1], Alireza Zali[2], Farzad Ashrafi[2], Reza Jalili-Khoshnoud[1], Zeinab Pakdelnia[3,4], Zahra Rostami[3,4], Kamran Rezaei[1]

[1] Men's Health and Reproductive Health Research Center, Shahid Beheshti University of Medical Sciences, Tehran, Iran
[2] Functional Neurosurgery Research Center, Research Institute of Functional Neurosurgery, Shohada Tajrish Neurosurgical Center of Excellence, Shahid Beheshti University of Medical Sciences, Tehran, Iran
[3] School of Medicine, Shahid Beheshti University of Medical Sciences, Tehran, Iran
[4] Student Research Committee, Shahid Beheshti University of Medical Sciences, Tehran, Iran

Keywords
Deep Brain Stimulation; Complication; Neurology; Neurosurgery

Abstract

Background: Deep brain stimulation (DBS) involves implanting electrodes in the brain to enhance movement and psychiatric functions. However, post-surgical complications can negatively impact patients' quality of life (QoL). This single-center study evaluates short- and long-term complications of DBS surgery to provide insights for improving outcomes.

Methods: Patients with Parkinson's disease (PD), dystonia, and essential tremor (ET) who underwent DBS implantation procedures from January 2016 to January 2024 in our center (Shohada Tajrish Hospital, Tehran, Iran) were surveyed.

Results: Among a total of 75 assessed patients, 47 individuals were available to be surveyed and analyzed continuously. The most frequent complications observed were battery protrusion (n = 20, 42.55%), bowstringing (n = 14, 29.78%), hypersalivation (n = 14, 29.78%), and itching at the suture site (n = 12, 25.53%). These complications were divided into three categories: operation-related, hardware-related, and other complications. The hardware-related category exhibited a wider range and a more prominent peak in the time–frequency plot. In contrast, the 'other complications' category—specifically apraxia of eyelid opening (AEO) and hypersalivation—demonstrated a more normal distribution pattern.

Conclusion: To obtain a better long-term success rate and provide an improved QoL, further investigations are warranted to better evaluate the leading causes of post-surgical DBS complications. These findings reflect complication patterns observed in a DBS cohort and do not imply direct causality.

How to cite this article: Salari M, Zali A, Ashrafi F, Jalili-Khoshnoud R, Pakdelnia Z, Rostami Z, et al. Complications of deep brain stimulation: A single-center survey. Curr J Neurol 2026; 25(1): 28-36.

Copyright © 2026 Iranian Neurological Association, and Tehran University of Medical Sciences
Published by Tehran University of Medical Sciences

Corresponding Author 1: Kamran Rezaei
Email: kamran_rezaei@yahoo.com
Corresponding Author 2: Zahra Rostami
Email: zahra.rstm@gmail.com

This work is licensed under a Creative Commons Attribution-NonCommercial 4.0 international license (http://creativecommons.org/licenses/by-nc/4.0/). Non-commercial purposes uses of the work are permitted, provided the original work is properly cited.

Introduction

Deep brain stimulation (DBS) is a well-established surgical procedure that involves the implantation of a neurostimulator in specific brain regions to deliver electrical impulses for alleviating symptoms associated with movement and neuropsychiatric disorders.[1] This technique is commonly used to address prevalent movement disorders such as Parkinson's disease (PD), essential tremor (ET), and dystonia.[2] The subthalamic nucleus (STN)—a key component of brain circuits responsible for motor, cognitive, and emotional functions—plays a crucial role in modulating behavior in individuals with PD, highlighting the therapeutic effectiveness of DBS in this patient population.[3]

On the other hand, although DBS presents therapeutic advantages for patients with PD, it is crucial to consider potential complications to ensure patient well-being.[4] Complications such as infections requiring revision surgery, intracranial bleeding, misplacement, and hardware-related issues like migration or malfunction have been identified, albeit with generally low occurrence rates, particularly in experienced centers.[4] Furthermore, DBS may carry a risk of cognitive decline, emphasizing the importance of a comprehensive evaluation of its benefits and drawbacks.[5]

Understanding the potential complications associated with DBS allows for the development of strategies to minimize these risks and optimize patient outcomes.[6] Regarding the scarcity of information for short- and long-term complications of DBS surgery in regions such as Iran, regional surveys can enhance the abovementioned goal. The present single-center study aimed to evaluate the short- and long-term complications in patients with PD, ET, and dystonia following DBS surgery. Studying the complications of DBS surgery offers several significant benefits in enhancing patient care and treatment outcomes.

Materials and Methods

Patients and clinical procedure: Patients with PD, dystonia, and ET who underwent DBS implantation procedures in our center (Shohada Tajrish Hospital, Tehran, Iran) from January 2016 to January 2024 were retrospectively surveyed and analyzed to collect the target data. All forms of intracranial electrode implantation were considered as the target criteria for patient selection in this study. Complications were retrospectively identified via comprehensive review of both postoperative records and follow-up visits in our clinical center between January 2016 and January 2024. All the patients' complaints that were clinically compatible with post-DBS implantation were considered as target complications in this survey. To note, the present study only reports the complications that occurred in a cohort of patients who underwent DBS surgery. However, to distinguish surgical complications from the natural course of disease progression, only a new-onset symptom or exacerbation of a clinical manifestation was considered a DBS complication. Events such as postoperative seizures in a patient diagnosed with epilepsy before the surgery were not included as complications due to a lack of certainty for them being the result of the surgery. The time range of the complications was based on follow-up visits at the clinic.

Itching at the suture site (patients' complaint), site infection, urinary incontinence, weight gain, and subdural hemorrhage were mentioned as the operation-related category, mainly due to the effect of the insertion location of the electrodes. The hardware-related category consisted of bowstringing, protrusion of the battery, and device dislocation. Finally, the 'other complications' category involved apraxia of eyelid opening (AEO) and hypersalivation.

DBS surgery: Prior to surgery, all patients underwent a positioning magnetic resonance imaging (MRI) using gadolinium-based contrast at our center. Based on the MRI results and a preoperative computed tomography (CT) scan, the positional aspects of the surgical approach were defined. A microelectrode recording (MER) conduction procedure was performed for intraoperative electrophysiological localization of STN, internal globus pallidus (GPi), and ventral intermediate nucleus (Vim) without using any sedative agents. Then a macro-stimulation was performed to confirm the correct placement of electrodes. Following general anesthesia, the implantable pulse generator (IPG) was placed into the subclavian pouch. Subsequently, the related wires were used to connect the electrodes and the IPG. Finally, the position of the electrodes was confirmed again using a postoperative CT review within 24 hours.

Statistical graphs and information: The statistical information and graphs provided in this study are prepared using Stata statistical software

(version 17, Stata Corporation, College Station, TX, USA) and Python 3.12.3. These included summarized clinical and demographic features of the study, descriptive bar charts, and scatter plot figures to better understand the distribution of the complications on a post-surgical time basis.

Results

Demographic and clinical features: A total of 75 DBS insertion procedures were performed at our center from January 2016 to January 2024, involving the implantation of 150 electrodes (75 pairs). Information for 5 cases was not available in this survey due to a lack of access to these patients in the follow-up visit courses. Regarding the other 70 available cases, the total number of PD, ET, and dystonia cases was 54, 2, and 14, respectively. The insertion sites included 53 pairs in STN for PD cases, 15 pairs in GPi (one for a patient with PD and 14 for patients with dystonia), and 2 pairs in Vim for patients with ET. Based on the retrospective study design, the available high-quality documentations were selected, consisting of 49 (90.7%) PD cases and one (7.1%) dystonia case showing at least one of the determined complications which emerged progressively during long-term follow-up. Three of the cases died before the start of this survey due to comorbidities and other etiologies not related to the DBS procedure and complications; thus, 47 living cases with a reported complication (out of a total of 75 cases with DBS insertion) were available for comparative presentation.

Demographic characteristics of 47 living cases with complications related to their DBS implantation are summarized in table 1. The cohort comprised 28 male (59.6%) and 19 female (40.4%) patients. The mean age of the cases was 53.40 years (ages were accounted as rounded numbers for years; months were not included). As shown in table 1, the interval between disease onset (mean age: 40.08 years) and surgery (mean age: 48.27 years) was 8.19 years. Regarding the total disease duration, the cohort exhibited a mean duration of 13.31 years. When stratified by diagnosis, the mean disease duration was 13.38 years for the 46 patients with PD and 10.00 years for the single patient with dystonia. Among the 47 patients who experienced post-implantation complications, 8 (17.0%) presented with a single complication, while 4 (8.5%) developed multiple complications. Body mass index (BMI) data were available for all 47 living patients. 12 patients (25.5%) had a BMI ≤ 23 kg/m², 5 (10.63%) were in the range of 23 < BMI ≤ 25 kg/m², 25 (53.19%) were in the range of 25 < BMI ≤ 30 kg/m², and 5 (10.63%) had a BMI between 30 and 35 kg/m². No patients in this cohort presented with a BMI ≥ 35 kg/m². The prevalence of pre-existing comorbidities among the patients was as follows: diabetes mellitus (DM) was the most frequent (n = 5), followed by arrhythmia, hypothyroidism, and dyslipidemia (each n = 3). Hypertension (HTN) and a history of interventional angiographic surgery were each reported in 2 patients. Additionally, single cases of epileptic syndromes, inflammatory bowel disease (IBD), and anemia were documented (Table 1).

Table 1. Demographic information of the patients who completed the survey (n = 47)

Demographics	Value	Minimum	Maximum
Movement disorder			
Parkinson's disease	46 (97.87)	-	-
Dystonia	1 (2.13)	-	-
Age (year)	53.40	36	73
Sex			
Men	28 (59.57)	-	-
Women	19 (40.43)	-	-
Duration of disease (year)	13.31	5	30
Age at disease onset (year)	40.08	14	63
Age at surgery (year)	48.27	32	65
Comorbidities = 1	8 (17.02)	-	-
Comorbidities > 1	4 (8.51)	-	-
BMI			
≤ 23	12 (25.53)	20	23
23 < BMI ≤ 25	5 (10.63)	24	25
25 < BMI ≤ 30	25 (53.19)	26	29
30 < BMI ≤ 35	5 (10.63)	31	32

Data are presented as mean or number and percentage.
BMI: Body mass index

Frequency distribution of the complications: As shown in table 2, 13 different complications were identified in patients who underwent DBS implantation at our center during the study period. To facilitate comparison and better illustrate the characteristics of these complications, they were divided into three categories.

Itching at the suture site (n = 12, 25.53%), site infection (n = 8, 17.02%), urinary incontinence (n = 5, 10.63%), weight gain (n = 8, 17.02%), and subdural hemorrhage (n = 1, 2.12%) were mentioned as operation-related categories. Itching at the suture site was a relatively common complication in this survey. Regarding weight gain, 4 patients (8.5%) gained less than 5 kg, while another 4 patients (8.5%) reported a weight gain of 5 kg or more.

Regarding hardware-related category, the frequencies were as follows: bowstringing (n = 14, 29.78%), protrusion of battery (n = 20, 42.55%), and device dislocation (n = 2, 4.25%). This category constituted a substantial proportion of the complications observed among DBS patients at our center. Protrusion of the battery was a common finding, involving almost half of the complication cases.

Additionally, seven (14.89%) and fourteen (29.78%) patients with complications presented with AEO and hypersalivation, respectively.

Time-related distribution of the complications: Table 2 summarizes the time to complication onset among the 47 surviving patients described in this study. The reporting interval was widest for battery protrusion (24–156 months; range = 132 months), followed by hypersalivation (4-108 months; range = 104 months) and AEO (6-108 months; range = 102 months). According to the frequency distribution, battery protrusion showed a relatively wide range of occurrence over the follow-up period.

Figure 1 provides an overview of the time-related distribution of frequencies of each complication. Six postoperative time intervals were defined, and the frequency of each complication within these intervals is presented as a bar chart. For less than 1 month and more than 60 months after the surgery, there was less variability in complications.

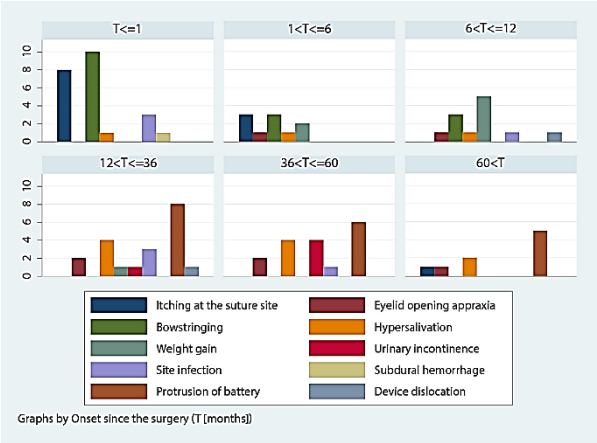

Figure 1. Bar chart showing the frequency of post-surgical deep brain stimulation (DBS) complications based on time (T, months). The time intervals are unequal and based on clinic follow-up schedules rather than statistical grouping.

Itching at the suture site was most frequent within the first month after DBS implantation, and showed a decreasing trend over the next months. The same is attributable to the bowstringing complication. Conversely, the protrusion of battery complication exhibited a later time of onset (12 < T ≤ 36 months), and demonstrated a nearly stable trend in frequency during the subsequent months.

Table 2. Descriptive statistics of complications of deep brain stimulation (DBS) surgery in the study population (n = 47)

Complications	n (%)	Minimum time to complication detection (month)	Maximum time to complication detection (month)
Itching at the suture site	12 (25.53)	1	84
Eyelid opening apraxia	7 (14.89)	6	108
Bowstringing	14 (29.78)	1	12
Hypersalivation	14 (29.78)	4	108
Weight gain	8 (17.02)		
Weight gain < 5 kg	4 (8.51)	2	12
Weight gain ≥ 5 kg	4 (8.51)	12	24
Urinary incontinence	5 (10.63)	36	60
Site infection	8 (17.02)	1	60
Subdural hemorrhage	1 (2.12)	1	1
Protrusion of battery	20 (42.55)	24	156
Device dislocation	2 (4.25)	9	24

It should be noted that the time intervals shown in figure 1 were not determined based on the statistical method of grouping data in frequency description, as a correct statistical method requires equal ranges for each group. But in our case, the groups do not show equal ranges, because the method for reporting a complication was based on follow-up visits at the clinic, and as the follow-up sessions were not planned for equal sets of time, it was not possible to make a correct statistical range of grouping data.

To provide a more consistent view of the time–frequency relation for the complications, figure 2 presents a scatter plot regarding frequency and time (after surgery, at which the complication is reported) as variables for each of the three abovementioned categories. The hardware-related category showed a wider range and a more prominent peak in the time–frequency plot. In contrast, the 'other complications' category was shown to have a more normal distribution pattern.

Discussion

The present study assessed the short- and long-term complications in patients with PD, dystonia, and ET who underwent DBS surgery at Shohada Tajrish Hospital in Tehran City. The complications associated with DBS can be broadly categorized into operation-related issues, hardware-related problems, stimulation-related effects, and cognitive disorders. The results demonstrated that the distribution and frequency of these complications varied significantly. It is important to note that this study solely documented the complications experienced by a group of patients who had undergone DBS surgery. In our study, we defined DBS complications as either a new-onset complication or the worsening of an existing clinical manifestation to reduce the challenge of differentiating a genuine DBS complication from the natural progression of the disease; however, there is still an important limitation regarding this differentiation. The stimulation-related complications were not evaluated due to the potential bias associated with the time of stimulation and stimulation settings across the patients, affected by the small sample size of the present study. The hardware-related category showed a wider range and a more prominent peak in the time–frequency plot. In contrast, the 'other complications' category was shown to have a more normal distribution pattern. Furthermore, while some issues occur earlier after surgery, others, like hardware-related problems, can persist or emerge later. This comprehensive analysis underscores the need for ongoing monitoring and tailored management strategies to address the diverse range of complications following DBS.

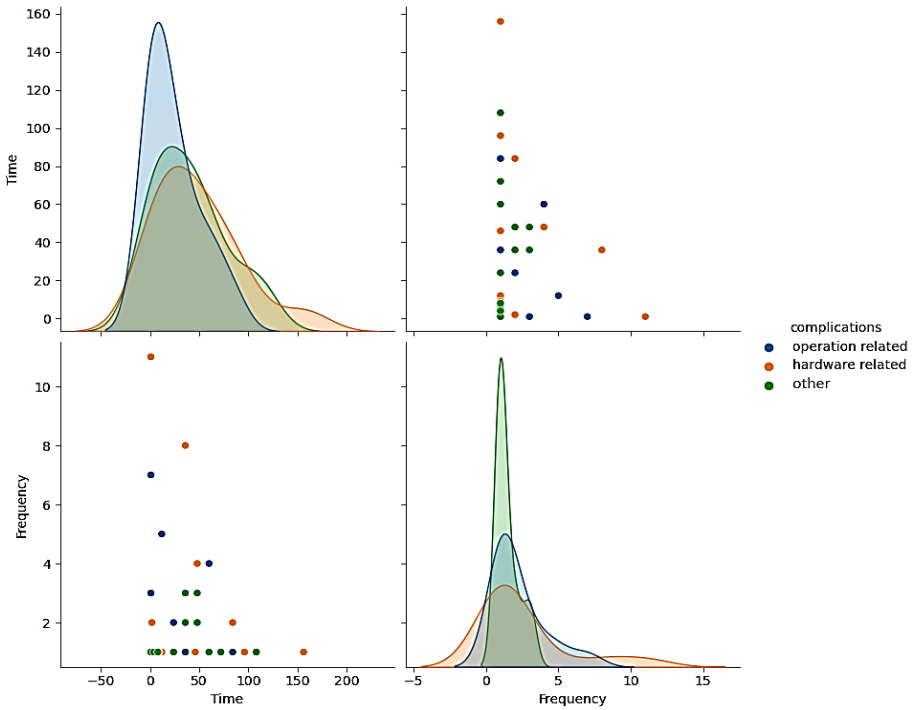

Figure 2. Scatter plot showing the time–frequency pattern across the four categories of post-surgical deep brain stimulation (DBS) complications

A notable limitation of the present study was the lack of precision regarding the time when a complication started, because the method for reporting a complication was based on follow-up visits at the clinic. Despite this constraint, characterization of the most common post-implantation complications of DBS surgery in this single-center study may provide valuable information for further assessments, qualifications, and improvements in this setting.

Research indicates that cognitive decline, particularly in areas such as verbal fluency, executive function, attention, working memory, and response inhibition, can occur following bilateral STN DBS.[7,8] These cognitive changes are more commonly observed in patients with preexisting cognitive impairments.[9] A longitudinal study found that within the first 3 postoperative months, no visual hallucinations were reported, but in the long term, approximately 10% of patients developed visual hallucinations.[10] Another study reported that new-onset visual hallucinations following STN DBS occurred in one case, indicating a rare but possible complication associated with the procedure.[11] Additionally, a case report highlighted that visual hallucination was induced by DBS in a patient with PD, further emphasizing the potential for this complication.[12] The time of occurrence of post-DBS surgery visual hallucination can vary. For instance, one study described its recurrence 3 years after surgery, time-locked with stimulation of an electrode within the zona incerta.[13] In another case, visual hallucination was reported to occur long after the initial postoperative period.[10] Moreover, the occurrence rate of speech disturbance complications in DBS surgery is approximately 2.0% based on the available data.[14] Speech dysfunction can manifest at various points during the postoperative period, emphasizing the importance of close monitoring of patients to detect and manage any speech-related issues that may arise.[15] In the present study, however, there was no decline in cognitive domains decisively attributable to the DBS post-surgical complications. In other words, the lack of documentation of patients' pre- and postoperative cognitive scores in this retrospective study made it impossible to determine whether any observed cognitive decline, if present, could be attributed to DBS surgery. However, the postoperative follow-up reports indicated no memory loss, hallucination, or psychological complaints in the patients. Patients, caregivers, neurologists, and neurosurgeons need to be aware of the potential cognitive complications of DBS surgery.

Studies have highlighted various operation-related complications that patients may encounter during or after DBS surgery. In the present study, itching at the suture site (25.53%), site infection (17.02%), urinary incontinence (10.63%), weight gain (17.02%), and subdural hemorrhage (2.12%) were mentioned as operation-related categories. These complications can have a significant impact on the patient's postoperative recovery and overall outcome. Specific complications associated with the surgical procedure may involve neurosurgical techniques, such as hematoma, subdural hemorrhage, and cerebral hemorrhage, as well as issues like urinary incontinence and weight gain.[16,17] Based on available data, the reported incidences of subdural hemorrhage, urinary incontinence, and weight gain complications in DBS surgery are approximately 1.4%,[18] 11.1%,[19] and 2.8%,[20] respectively. Studies have shown that older patients undergoing DBS surgery have a similar risk of complications compared to younger patients, including postoperative hemorrhage or infection.[20] Infections related to the DBS device are recognized as a significant complication that can impact the course of DBS therapy, necessitating careful management and potential hardware removal.[21] The percentage of site infection complications in DBS surgery varies across studies, with rates reported between 1.5% and 6.1%.[16] In general, the frequency of inflammatory responses, infection, and hemorrhage was relatively compatible with other reports.[22] These complications are mostly due to the nature of the surgery (mostly the surgical site characteristics) and patients' status of wound care.[22]

In addition, hardware-related complications unique to DBS, such as foreign-body migration and stimulation-induced side effects, can pose challenges for patients undergoing DBS surgery.[17] Regarding the hardware-related category, the frequencies observed in this study were as follows: bowstringing (29.78%), protrusion of battery (42.55%), and device dislocation (4.25%). Factors such as comorbid medical conditions, HTN, early-stage operation, and unilateral electrode implantation have been identified as potential risk factors for overall complications, including operation-related issues.[23] Moreover, the development of peri-lead edema or cystic cavitation post-DBS surgery underscores the importance of monitoring patients for both

immediate and delayed complications that may arise from intracranial and hardware-related events.[24,25] The percentage of bowstringing complications in DBS surgery is approximately 2.0% based on available data.[26] The study by Miller and Gross highlights wire tethering or 'bowstringing' as a long-term hardware-related complication of DBS, emphasizing the need for surgical revision in such cases.[26] In terms of battery protrusion, it occurs in approximately 2.0% of cases as previously reported,[27] and can arise at any time after surgery, particularly following repeated IPG replacements due to battery drain.[28] Device dislocation, reported to occur in approximately 2.0% of DBS procedures,[29] is a hardware-related complication, which may necessitate surgical intervention to address the issue. Similar to other hardware-related complications, such as lead fracture and infection, it is a known risk associated with DBS surgery.[29]

The relatively high rate of battery protrusion in these patients may be attributable to the high frequency of infection or inflammation at the site discussed earlier, both of which have been reported as important causes of this complication.[30] Furthermore, the rate of bowstringing was relatively high among patients who experienced complications in our study. While the surgical technique of tunneling over the convexity of the clavicle—rather than directing towards the suprasternal notch—is recognized to mitigate the risk of bowstringing,[31] the high incidence may be due to the lack of a clear method of reporting this complication in the medical records. Specifically, reliance on subjective patient reports, such as self-perceived tightening along the lead path, may contribute to a high false-positive rate for bowstringing.

Stimulation-related complications of DBS surgery, which may result from excessive or insufficient stimulation of specific target nuclei, including AEO, hypersalivation, and seizures, are important considerations in the management of movement disorders. Results showed that 14.89%, 29.87%, and 4.25% of the complications were related to AEO, hypersalivation, and seizure, respectively. Studies have reported that AEO can occur in patients undergoing STN stimulation, highlighting the need for vigilance in monitoring and managing this complication.[18,32] The percentage of AEO complications in DBS surgery ranges from 1.8% to 30% according to previous reports.[33] This complication may persist during the long-term follow-up in DBS patients; therefore, rigorous clinical surveillance is essential for both early detection and management.[32] Hypersalivation is another stimulation-related complication that can arise post-DBS surgery. While not as common as other side effects, hypersalivation has been reported in a subset of patients undergoing DBS, necessitating careful assessment and potential adjustments of stimulation parameters.[34] Moreover, seizures represent a serious but relatively uncommon stimulation-related complication of DBS surgery. Their occurrence in some patients underscores the importance of close monitoring and prompt intervention in cases where seizures develop postoperatively.[23] The percentage of seizure complications in DBS surgery ranges from 1.1% to 4.6% based on the reported evidence.[35] The exact timing of the occurrence of post-DBS surgery seizures varies, with at least 74% of seizures reported to occur around the time of electrode implantation.[36] Proper evaluation of seizure risk factors and adjustment of stimulation parameters may be necessary to mitigate the occurrence of seizures in individuals undergoing DBS therapy.[37] In our study, AEO was potentially due to factors such as stimulation of certain nuclei (e.g., the STN) or the patient's nature of disease (PD in particular).[37] Regarding hypersalivation, it is presumed to be primarily a symptom of the underlying disease rather than a complication of the DBS insertion surgery.[4,37]

The next step for further investigation may involve case-control studies engaging multiple surgical settings to better evaluate the leading cause of most of the post-surgical DBS complications, and how we can improve the results. Healthcare providers must be aware of these complications associated with DBS surgery to ensure timely recognition and appropriate management. By closely monitoring patients for symptoms, healthcare teams can optimize patient outcomes and quality of life (QoL) following DBS surgery.

Limitations: One significant limitation of this retrospective study is the absence of scoring systems in the patients' medical records, which restricts the categorization of complications, especially cognitive complications. Additionally, it is important to note that nearly one-third of the patients who underwent DBS surgery did not have follow-up reports. This lack of follow-up significantly reduced the study population for this study, which could potentially influence the

frequency and types of complications reported. Moreover, the reported timing of complications is imprecise, and some reported frequencies may be inaccurate due to inconsistent data collection. Conducting a prospective study with a bigger sample size that systematically collects mental and motor scoring systems could enable researchers to draw more accurate conclusions about the complications associated with DBS insertion surgery. Furthermore, examining various stimulation-related complications, such as gait disturbances and dysarthria, in a sufficiently large sample can significantly enhance our understanding of both short- and long-term complications following DBS surgery and provide a stronger basis for future experimental studies and robust statistical inference. Ultimately, it is crucial to note that this study exclusively reports the complications observed in a cohort of patients who underwent DBS surgery. In this study, we characterized DBS complications as either a newly occurring complication or the exacerbation of a pre-existing clinical manifestation to mitigate the difficulty of distinguishing a true DBS complication from the natural progression of the disease. However, there remains a significant limitation concerning this differentiation.

Conclusion

In summary, this single-center retrospective analysis suggests that while hardware-related issues are the most frequent complications after DBS, these adverse events may follow a time-dependent pattern, with non-hardware events tending to occur in the immediate postoperative phase and hardware-related issues emerging later. These temporal patterns are descriptive and do not establish causality; nevertheless, they highlight a substantial, potentially preventable postoperative burden that warrants targeted quality-improvement efforts. To strengthen the evidence base in our region and improve long-term outcomes after DBS, prospective, multicenter studies are needed, using pre-specified and harmonized complication definitions, standardized follow-up intervals with transparent retention reporting, and precise event dating to enable robust time-to-event analyses. Critically, future work should incorporate uniform motor and cognitive assessments at baseline and during follow-up [e.g., Unified PD Rating Scale (UPDRS) and Montreal Cognitive Assessment (MoCA), ideally complemented by domain-specific cognitive testing] to reliably capture cognitive trajectories and differentiate stimulation-, device-, and surgery-related effects from underlying disease progression. Establishing a coordinated registry across high-volume DBS centers, with independent event adjudication and stratification by indication, target, and device type, would provide the statistical power and generalizability needed to guide evidence-based postoperative care. Embedding and evaluating a structured patient-navigation pathway within this framework could further determine whether standardized postoperative management reduces complications and improves QoL.

Conflict of Interests

The authors declare no conflict of interest in this study.

Acknowledgments

We hereby thank all the patients who participated in this study for their invaluable contribution to the collection of clinical data.

This article has benefited from the disease registry, titled "Parkinson's Disease Registry in patients referred to Neurology Clinics of Shahid Beheshti University of Medical Sciences in Tehran (SBMU-PDR)" with the code number IR.SBMU.RETECH.REC.1398.439 from ethics committee supported by the deputy of research and technology at Shahid Beheshti University of Medical Sciences.

References

1. Benabid AL, Chabardes S, Mitrofanis J, Pollak P. Deep brain stimulation of the subthalamic nucleus for the treatment of Parkinson's disease. Lancet Neurol 2009; 8(1): 67-81.
2. Kleiner-Fisman G, Herzog J, Fisman DN, Tamma F, Lyons KE, Pahwa R, et al. Subthalamic nucleus deep brain stimulation: summary and meta-analysis of outcomes. Mov Disord 2006; 21(Suppl 14): S290-304.
3. Krack P, Batir A, Van Blercom N, Chabardes S, Fraix V, Ardouin C, et al. Five-year follow-up of bilateral stimulation of the subthalamic nucleus in advanced Parkinson's disease. N Engl J Med 2003; 349(20): 1925-34.
4. Jung IH, Chang KW, Park SH, Chang WS, Jung HH, Chang JW. Complications after Deep Brain Stimulation: A 21-Year Experience in 426 Patients. Front Aging Neurosci 2022; 14: 819730.
5. Krauss JK, Lipsman N, Aziz T, Boutet A, Brown P, Chang JW, et al. Technology of deep brain stimulation: current status and future directions. Nat Rev Neurol 2021; 17(2): 75-87.
6. Doshi PK. Long-term surgical and hardware-related complications of deep brain stimulation. Stereotact Funct

Neurosurg 2011; 89(2): 89-95.
7. York MK, Dulay M, Macias A, Levin HS, Grossman R, Simpson R, et al. Cognitive declines following bilateral subthalamic nucleus deep brain stimulation for the treatment of Parkinson's disease. J Neurol Neurosurg Psychiatry 2008; 79(7): 789-95.
8. Williams AE, Arzola GM, Strutt AM, Simpson R, Jankovic J, York MK. Cognitive outcome and reliable change indices two years following bilateral subthalamic nucleus deep brain stimulation. Parkinsonism Relat Disord 2011; 17(5): 321-7.
9. Kyrtsos CR, Stahl MC, Eslinger P, Subramanian T, Lucassen EB. Capgras Syndrome in a Patient with Parkinson's Disease after Bilateral Subthalamic Nucleus Deep Brain Stimulation: A Case Report. Case Rep Neurol 2015; 7(2): 127-33.
10. Yoshida F, Miyagi Y, Kishimoto J, Morioka T, Murakami N, Hashiguchi K, et al. Subthalamic nucleus stimulation does not cause deterioration of preexisting hallucinations in Parkinson's disease patients. Stereotact Funct Neurosurg 2009; 87(1): 45-9.
11. Anderson KE, Mullins J. Behavioral changes associated with deep brain stimulation surgery for Parkinson's disease. Curr Neurol Neurosci Rep 2003; 3(4): 306-13.
12. Diederich NJ, Alesch F, Goetz CG. Visual hallucinations induced by deep brain stimulation in Parkinson's disease. Clin Neuropharmacol 2000; 23(5): 287-9.
13. Voon V, Kubu C, Krack P, Houeto JL, Tröster AI. Deep brain stimulation: neuropsychological and neuropsychiatric issues. Mov Disord 2006; 21(Suppl 14): S305-27.
14. Umemura A, Oyama G, Shimo Y, Nakajima M, Nakajima A, Jo T, et al. Current Topics in Deep Brain Stimulation for Parkinson Disease. Neurol Med Chir (Tokyo) 2016; 56(10): 613-25.
15. Deuschl G, Herzog J, Kleiner-Fisman G, Kubu C, Lozano AM, Lyons KE, et al. Deep brain stimulation: postoperative issues. Mov Disord 2006; 21(Suppl 14): S219-37.
16. Voges J, Waerzeggers Y, Maarouf M, Lehrke R, Koulousakis A, Lenartz D, et al. Deep-brain stimulation: long-term analysis of complications caused by hardware and surgery--experiences from a single centre. J Neurol Neurosurg Psychiatry 2006; 77(7): 868-72.
17. Xu S, Wang W, Chen S, Wu Q, Li C, Ma X, et al. Deep Brain Stimulation Complications in Patients With Parkinson's Disease and Surgical Modifications: A Single-Center Retrospective Analysis. Front Hum Neurosci 2021; 15: 684895.
18. Kpatcha TM, Tchangai B, Tengue K, Alassani F, Botcho G, Darre T, et al. Experience with Open Prostatectomy in Lomé, Togo. Open J Urol 2016; 6(5): 73-9.
19. Strowd RE, Cartwright MS, Passmore LV, Ellis TL, Tatter SB, Siddiqui MS. Weight change following deep brain stimulation for movement disorders. J Neurol 2010; 257(8): 1293-7.
20. DeLong MR, Huang KT, Gallis J, Lokhnygina Y, Parente B, Hickey P, et al. Effect of advancing age on outcomes of deep brain stimulation for Parkinson disease. JAMA Neurol 2014; 71(10): 1290-5.
21. Baizabal-Carvallo JF, Kagnoff MN, Jimenez-Shahed J, Fekete R, Jankovic J. The safety and efficacy of thalamic deep brain stimulation in essential tremor: 10 years and beyond. J Neurol Neurosurg Psychiatry 2014; 85(5): 567-72.
22. Peppe A, Paravati S, Baldassarre MG, Bakdounes L, Spolaor F, Guiotto A, et al. Proprioceptive Focal Stimulation (Equistasi®) May Improve the Quality of Gait in Middle-Moderate Parkinson's Disease Patients. Double-Blind, Double-Dummy, Randomized, Crossover, Italian Multicentric Study. Front Neurol 2019; 10: 998.
23. Lu Y, Qiu C, Chang L, Luo B, Dong W, Zhang W, et al. Development of Unilateral Peri-Lead Edema Into Large Cystic Cavitation After Deep Brain Stimulation: A Case Report. Front Neurol 2022; 13: 886188.
24. Borellini L, Ardolino G, Carrabba G, Locatelli M, Rampini P, Sbaraini S, et al. Peri-lead edema after deep brain stimulation surgery for Parkinson's disease: a prospective magnetic resonance imaging study. Eur J Neurol 2019; 26(3): 533-9.
25. Tabaja H, Yuen J, Tai DBG, Campioli CC, Chesdachai S, DeSimone DC, et al. Deep Brain Stimulator Device Infection: The Mayo Clinic Rochester Experience. Open Forum Infect Dis 2023; 10(1): ofac631.
26. Miller PM, Gross RE. Wire tethering or 'bowstringing' as a long-term hardware-related complication of deep brain stimulation. Stereotact Funct Neurosurg 2009; 87(6): 353-9.
27. Hannani S, Beigi-Khoozani A, Afshar-Zarandi A. Evaluating the Longevity of Implantable Pulse Generator Used in Deep Brain Stimulation: A Systematic Review. Iran J Neurosurg 2022; 8(1): E7.
28. Rossi M, Bruno V, Arena J, Cammarota Á, Merello M. Challenges in PD Patient Management After DBS: A Pragmatic Review. Mov Disord Clin Pract 2018; 5(3): 246-54.
29. Hariz MI. Complications of deep brain stimulation surgery. Mov Disord 2002; 17(Suppl 3): S162-6.
30. Doshi PK, Rai N, Das D. Surgical and Hardware Complications of Deep Brain Stimulation-A Single Surgeon Experience of 519 Cases Over 20 Years. Neuromodulation 2022; 25(6): 895-903.
31. Akram H, Limousin P, Hyam J, Hariz MI, Zrinzo L. Aim for the Suprasternal Notch: Technical Note to Avoid Bowstringing after Deep Brain Stimulation. Stereotact Funct Neurosurg 2015; 93(4): 227-30.
32. Umemura A, Oka Y, Yamamoto K, Okita K, Matsukawa N, Yamada K. Complications of subthalamic nucleus stimulation in Parkinson's disease. Neurol Med Chir (Tokyo) 2011; 51(11): 749-55.
33. Grimes D, Gordon J, Snelgrove B, Lim-Carter I, Fon E, Martin W, et al. Canadian Guidelines on Parkinson's Disease. Can J Neurol Sci 2012; 39(4 Suppl 4): S1-30.
34. Bakay R, Smith A. Deep brain stimulation: Complications and attempts at avoiding them. Open Neurosurg J 2011; 4(Suppl 1-M4): 42-52.
35. Chen T, Mirzadeh Z, Chapple K, Lambert M, Ponce FA. Complication rates, lengths of stay, and readmission rates in “awake” and “asleep” deep brain simulation. J Neurosurg 2017; 127(2): 360-9.
36. Coley E, Farhadi R, Lewis S, Whittle IR. The incidence of seizures following Deep Brain Stimulating electrode implantation for movement disorders, pain and psychiatric conditions. Br J Neurosurg 2009; 23(2): 179-83.
37. Orcutt T, Vitek J, Patriat R, Harel N, Matsumoto J. Apraxia of Eyelid Opening Improved by Pallidal Stimulation in Progressive Supranuclear Palsy. Mov Disord Clin Pract 2020; 7(6): 698-700.